

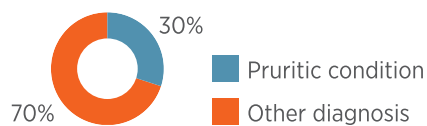
Building Blocks of Dermatology Diagnostics: The Importance of Cytology in Dermatology

Michele Rosenbaum, VMD, Dipl. ACVD | Cory Penn, DVM | Anonda Haskin, DVM

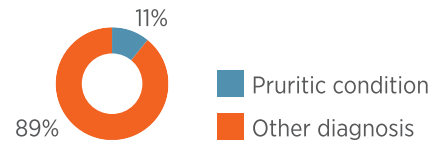
Introduction

Dermatologic cases, including skin and ear disease, make up a significant portion of a small animal veterinarian's daily caseload.¹⁻³ In the United States, a recent survey of veterinarians indicated that 30% of dogs and 11% of cats are treated for pruritic conditions.¹ These cases require proper attention and handling, as dermatologic disease can affect the quality of life of both the patient and the pet owner.⁴

Canine Patients Treated for Pruritus¹



Feline Patients Treated for Pruritus¹



Diagnostic "Derm" Toolbox⁵

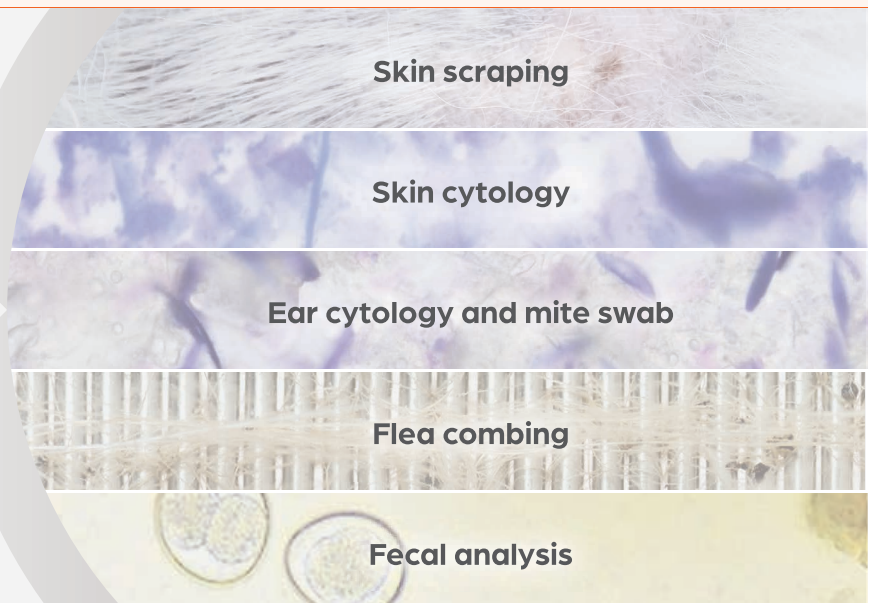- Flea comb
- No. 10 scalpel blade/spatula
- Mineral oil
- Clear tape
- Glass slides with a frosted end
- Pencil
- Cotton swabs
- Culturettes
- 25 gauge needles

When initially investigating these cases, the veterinarian should start the diagnostic workup with a thorough inquiry of the patient's medical history. A physical examination, including an assessment of the patient's skin, should also be conducted.⁵ After this information has been gathered, a differential diagnosis list can be assembled, and the selection of further diagnostic testing can be determined.⁴ In a pruritic patient, the recommended dermatologic minimum database includes a skin scraping, skin cytology (impression smears or swabs), ear cytology, mineral oil prep for ear mites, flea combing and fecal analysis (Figure 1).^{*} A preassembled dermatology toolbox allows the practitioner to easily collect samples wherever the patient may be located in the hospital.⁵

Dermatology diagnostics provide essential information to rapidly narrow down the list of differentials in patients with skin disease

Figure 1

Minimum Diagnostic Dermatology Database



^{*}All puppies, kittens and adult cats should have a fungal culture. This is also necessary in adult dogs with a supporting history (eg, lack of response to antibiotics, exposure to a new kitten from a shelter).

Dermatologic cytology

“Cytology” is defined as the microscopic examination of individual cells or groups of cells to identify their origin and any changes characteristic of disease.⁶ Skin is ideal for this useful diagnostic procedure because it is a large external organ that is easily accessible.⁷ In addition, pet owners are more likely to be open to skin cytology because they can easily visualize and feel the lesions.⁷

Cytology is an important and commonly used diagnostic tool in dermatology cases to determine the presence of inflammatory cells and, in many cases, infectious agents that are involved in their pathogenesis.⁸ It also aids in monitoring the success of various treatment modalities by helping practitioners determine the changes in organism numbers and inflammatory cells over time.

Lastly, cytology is a cost-effective diagnostic procedure and will generate income for a veterinary practice while providing essential information for managing patients.

There are three main aspects of cytological testing^{9,10}:

- Selection of the proper lesions or locations from which to collect samples
- Proper collection of materials and slide preparation
- Interpretation of the findings

Providing the rationale and explanation behind dermatology diagnostic workups can help pet owners see the value of the proposed testing. Frame recommendations for diagnostics in terms of the benefits to the well-being of the patient and their owner. For example, the practitioner could say:

“This diagnostic testing will help tell us what is causing Bosco’s skin problem so that we can best treat him to give you both the relief you need. I know you will both sleep so much better once his skin problem is cleared up.”

Skin surface cytology—when, why and how?

As stated, cytology is an important and powerful tool that can help narrow a differential diagnosis list and provide guidance in proper treatment selection in patients with a dermatologic condition.⁸ Clinical scenarios in which skin cytology should be performed include but are not limited to:

- Evidence of pyoderma: papules, pustules, collarettes, crusts
- Alopecia; hyperpigmentation; greasy, malodorous skin; waxy material around base of nails; brown staining (suspect *Malassezia*)
- When patient has not responded to empirical therapy

Skin impression smears can be collected directly or indirectly, depending on the cutaneous lesion.⁵ Direct impression smears are suitable for exudative lesions, including but not limited to erosions, ulcers, furuncles and the underside of crusts.⁵ For these lesions, the practitioner can press a frosted-ended slide multiple times onto the lesion, as long as the practitioner is careful not to rub too hard or move the slide side to side, which can rupture

cells. The use of forceps or the edge of the slide to gently lift a crust to reveal the moist lesion underneath is helpful for obtaining a diagnostic sample. For pustules, the practitioner can successfully sample the lesion by gently rupturing it with a 25 gauge needle and then lightly pressing the slide onto the open pustule.⁵

Skin impression smears can also be collected indirectly, with the use of a tape technique, cotton swab, dull blade, spatula or wooden applicator stick (helpful for nail beds). These collection techniques can be used in cases in which a direct impression smear is difficult to collect due to the cutaneous lesion’s location.⁵

Samples collected with swabs should always be “rolled” in one direction onto the microscope slide to avoid damaging the cells.¹¹ This is crucial for inflammatory lesions, as the back-and-forth motion of the swab against the slide can result in distortion of the cells. This is a good technique for face folds, tail folds and interdigital areas.

Ear cytology—when, why and how?

Ear disease is one of the most common reasons for owners to bring pets to the veterinarian for treatment, and it is estimated that otitis (inflammation of the pinna and ear, including the ear canal) affects up to 15% to 20% of the canine population.¹² All patients with clinical signs associated with otitis externa should undergo a bilateral ear cytology.¹²

The practitioner collects ear cytological samples by inserting a cotton swab, typically to the level of the junction of the vertical and horizontal ear canals.¹² The material from each ear canal is then gently rolled onto a clean glass slide.¹² The practitioner should roll the swab in one direction across the slide to avoid damaging cells.¹¹ A study from 2005 showed that cytology of otic exudate collected from the vertical ear canal correlated with the results from a bacterial culture of the same exudate.¹³

The same glass slide may be used for individual samples from the left and right ears. The sample obtained from each ear should be clearly marked on the slide, and each hospital should be sure to have a clearly defined standard operating procedure for placement on the slide.

Processing of dermatologic cytology samples

After placing the cytological sample on the labeled microscope slide with the frosted end, the practitioner lets the sample air dry prior to staining.⁵ The slide is then stained using a quick Romanowsky-type stain, closely following the stain manufacturer’s recommended protocol.⁵ Due to potential contamination, stains should ideally be changed weekly and the stain containers washed thoroughly in the process.

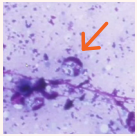


Interpretation of dermatologic cytology samples

When evaluating a cytological sample, determine whether there are inflammatory cells present and, if so, which ones. It is important to identify the number of infectious organisms (cocci, rods) seen per oil-immersion field (OIF) that may be involved in the pathogenesis of the skin lesions seen.⁸ To effectively analyze a

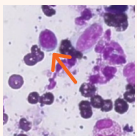
sample for abnormalities, it is important to understand which findings can be normal. Normal findings on cutaneous cytology can include anuclear or nuclear keratinocytes; melanin granules, either free or within keratinocytes; and surface debris.¹⁰ Bacteria and yeasts can also be normal inhabitants in low numbers.^{7,15}

Inflammatory Cells*



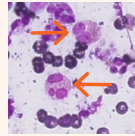
Neutrophils

- Presence is often a result of bacterial infection but may be seen in yeast infections and noninfectious dermatologic cases as well⁷
- A neutrophil can be classified as **degenerate**, meaning the cell can appear to have nuclear swelling with paler-staining chromatin. Presence of degenerate neutrophils should raise clinical suspicion of infection⁷



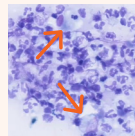
Lymphocytes

- Increased numbers are suggestive of chronic inflammation or immunological activity⁷
- Can be seen with arthropod stings or bites and with vaccine reactions⁷



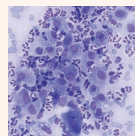
Eosinophils

- Increased numbers on the skin can occur as a result of a hypersensitivity response to an arthropod bite or sting⁷
- Increased numbers are also often seen in cases of allergic dermatitis and in cats with eosinophilic plaques



Macrophages

- Increased numbers on the skin can typically be indicative of chronic inflammation⁷




Mixed Cell Inflammation

- Implies that macrophages are present, with a mixture of other inflammatory cells, including lymphocytes and neutrophils⁷
- Often seen in deep nodular pyodermas, such as interdigital furunculosis (cysts) or chin acne⁹

*High-resolution images from VETSCAN IMAGYST.

Infectious Agents

When evaluating the sample for infectious agents, the veterinary professional must identify the types of organisms present (cocci, rods, yeast) in addition to whether they exist alongside or within inflammatory cells and whether the sample contains a single or a mixed population.

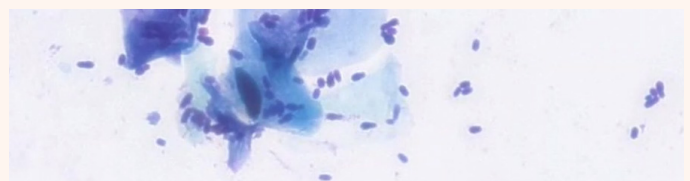


Bacteria (cocci and rods)

- Identification of the exact species of bacteria isn't possible. Only the differentiation of cocci vs rods can be made
 - *Staphylococcus pseudintermedius* is the most common cocci identified on skin
 - The identification of cocci (which can appear in grape-like clusters or pairs/tetrads) vs rods and the observation of notable volumes of bacteria are often enough to initiate antimicrobial therapy^{14,15}
- Normal skin has a microbial flora that is composed of resident and transient bacteria, so the finding of a low number does not indicate an abnormality^{14,15}
- Bacterial overgrowth is a large number of bacteria on the skin surface without evidence of neutrophils or intracellular bacteria on cytology. It can contribute to pruritus and skin inflammation and is common in dogs with underlying allergic dermatitis^{14,15}
- Superficial or deep pyoderma is classified based on the depth of bacterial involvement in the skin. Superficial pyoderma (or superficial bacterial folliculitis) involves the

epidermis and follicular epithelium. Deep pyoderma (or deep folliculitis and furunculosis) involves tissues deeper than the hair follicle, with hair follicle rupture and invasion of the dermis and often the subcutaneous tissue¹⁵

- The finding of degenerating neutrophils and intracellular bacteria supports the diagnosis of a pyoderma¹⁵
- Deep pyodermas usually have fewer extracellular bacteria present in favor of more intracellular bacteria with a mixed cellular infiltrate of macrophages, neutrophils and lymphocytes¹⁰



Yeast (*Malassezia pachydermatis*)

- Considered to be a normal inhabitant of the skin in low numbers, so the finding of a "few" organisms does not necessarily indicate infection⁷
- Overgrowth of yeast could occur secondary to allergic dermatitis, bacterial pyoderma, conformation problems or antibiotic use⁷
 - Some animals can have a hypersensitivity reaction to just a few organisms¹⁵

Dermatologic diagnostic testing informs clinical decisions

Dermatologic case diagnostic workups are immensely valuable and provide rapid feedback for the management of dermatology cases. The information that cytology provides is often the key diagnostic element that determines the best therapy for that patient. However, a recent survey of veterinarians in the United States found that only 41% of dogs and 35% of cats who presented with and were treated for pruritic conditions received diagnostic testing during their visit.¹

Of the veterinarians surveyed, 49% indicated that more skin cytological testing should be conducted.¹ In instances in which testing was not performed, the following barriers were communicated¹:

- Cost (financial strain on pet owner)
- Time spent by veterinary staff preparing/reading the tests and increased time spent by the pet owner in the hospital
- Comfort level performing the tests due to lack of training and short staffing

The survey respondents were also asked about the various responsibilities at different testing phases for skin and ear cytological testing in their hospitals.¹ It was found that the veterinarian and veterinary technician shared the responsibilities of preparing and evaluating the sample.¹ However, the veterinarian often confirms the result of the cytological evaluation, which leads to a less efficient workflow.¹

With the use of the VETSCAN IMAGYST™

AI Dermatology application, challenges surrounding workflow and the time it takes to read samples can be effectively alleviated. Further, the veterinary practitioner can have confidence in the accuracy of results for skin impression smears along with those for ear and skin swab cytological samples.



References: **1.** Data on file, Study: Impact of IMAGYST AI Diagnostic Tool on Current Cytology Testing Landscape, C-Space 2022, Zoetis Inc. **2.** Hill PB, Lo A, Eden CAN, et al. Survey of the prevalence, diagnosis and treatment of dermatological conditions in small animals in general practice. *Vet Rec.* 2006;158:533-539. doi: 10.1136/vr.158.16.533. **3.** Nationwide®. Dermatitis, otitis externa among most common conditions that prompt veterinary visits. March 28, 2022. Accessed November 15, 2022. <https://news.nationwide.com/032822-most-common-conditions-that-prompt-veterinary-visits//>. **4.** Bergvall K. History, examination and initial evaluation. In: Jackson H, Marsella R, eds. *BSAVA Manual of Canine and Feline Dermatology*. 4th ed. British Small Animal Veterinary Association; 2022:13-23. **5.** Paterson S. Core investigation and laboratory techniques. In: Jackson H, Marsella R, eds. *BSAVA Manual of Canine and Feline Dermatology*. 4th ed. British Small Animal Veterinary Association; 2022:24-31. **6.** Monti P, Cian F. Diagnostic cytology. In: Villiers E, Ristic J, eds. *BSAVA Manual of Canine and Feline Clinical Pathology*. 3rd ed. British Small Animal Veterinary Association; 2016:398-434. **7.** Fisher D. Cutaneous and subcutaneous lesions. In: Cowell RL, Valenciano AC. *Cowell and Tyler's Diagnostic Cytology and Hematology of the Dog and Cat*. 5th ed. Elsevier; 2019:74-101. **8.** Albanese F. Cytology. In: Jackson H, Marsella R, eds. *BSAVA Manual of Canine and Feline Dermatology*. 4th ed. British Small Animal Veterinary Association; 2021:32-40. **9.** Noxon JO, Goldman EE. Practical cytology. In: Rhodes KH, Werner AH, eds. *Blackwell's Five-Minute Veterinary Consult Clinical Companion: Small Animal Dermatology*. 3rd ed. Wiley-Blackwell; 2018:43-58. **10.** Mendelsohn CL, Rosenkrantz W, Griffin CE. Practical cytology for inflammatory skin diseases. *Clin Tech Small Anim Pract.* 2006;21(3):117-127. doi: 10.1053/j.ctsap.2006.05.004. **11.** Meinkoth FH, Cowell RL, Tyler RD, et al. Sample collection and preparation. In: Valenciano AC, Cowell RL. *Cowell and Tyler's Diagnostic Cytology and Hematology of the Dog and Cat*. 5th ed. Elsevier; 2019:1-17. **12.** Bensignor E. An approach to otitis. In: Jackson H, Marsella R, eds. *BSAVA Manual of Canine and Feline Dermatology*. 4th ed. British Small Animal Veterinary Association; 2022:143-149. **13.** Cole LK, Kwochka KW, Hillier A, et al. Comparison of bacterial organisms and their susceptibility patterns from otic exudate and ear tissue from the vertical ear canal of dogs undergoing a total ear canal ablation. *Vet Ther.* 2005 fall;6(3):252-259. **14.** Miller WH, Griffin CE, Campbell KL. Diagnostic methods. In: Miller WH, Griffin CE, Campbell KL, eds. *Muller & Kirk's Small Animal Dermatology*. 7th ed. Saunders; 2012:57-107. **15.** Scott D, Miller WH. Bacterial skin diseases. In: Scott D, Miller WH, Griffin CE, eds. *Muller & Kirk's Small Animal Dermatology*. 6th ed. Saunders; 2000:274-335.