



ZOETIS DIAGNOSTICS

**vetscan** Imagyst®

## Clinical and Consultation Case Report Examples



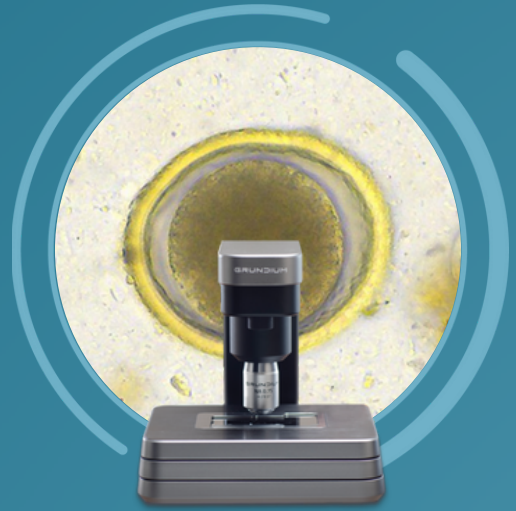
LOOK DEEPER

**zoetis**

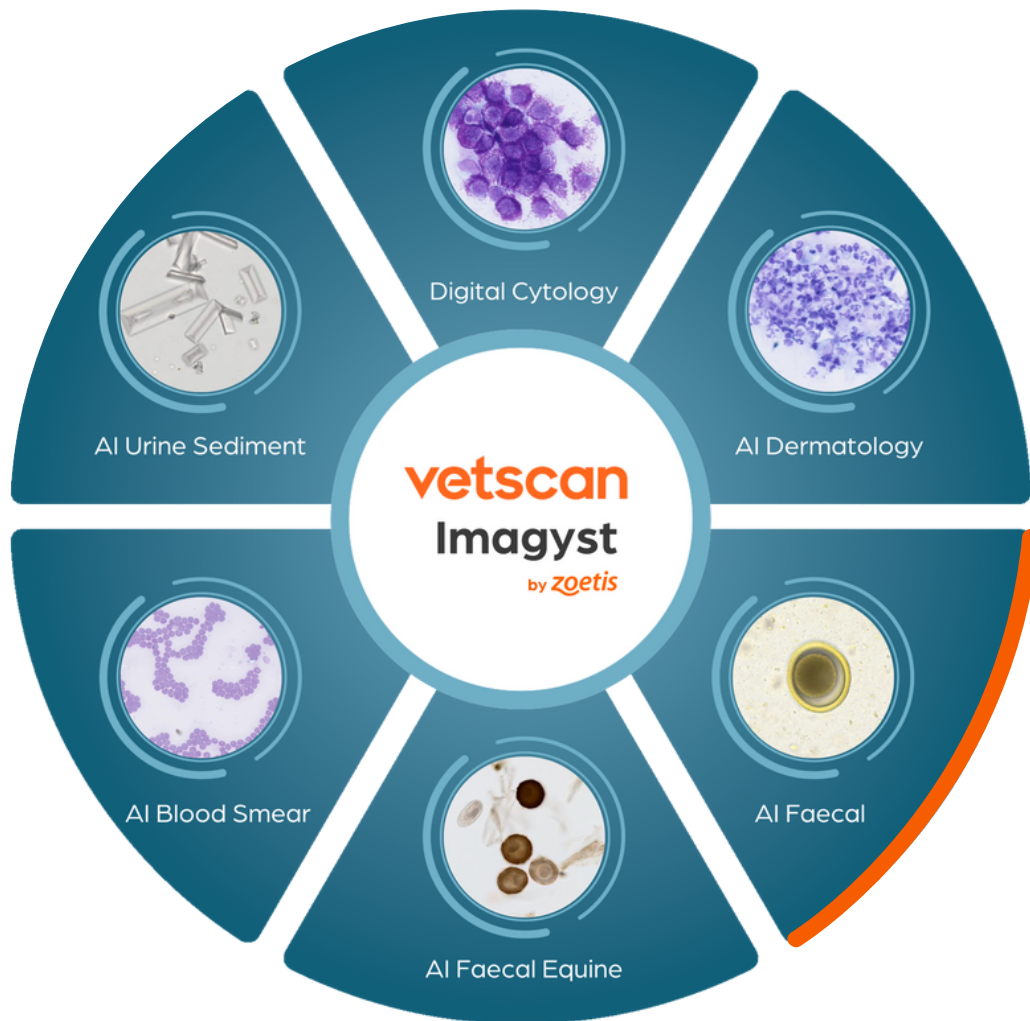
ZOETIS DIAGNOSTICS

**vetscan** Imagyst®

# AI Canine/Feline Faecal Reports



Part of the unique, multi-application  
Vetscan Imagyst platform from Zoetis



LOOK DEEPER

**zoetis**

Patient ID:  
Test ID:  
Species: Canine

Clinic/Hospital:  
  
Finalized Date:

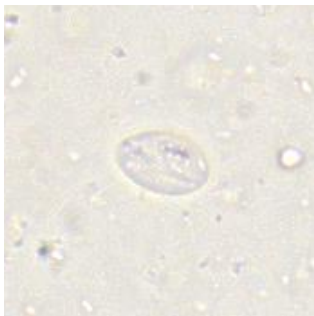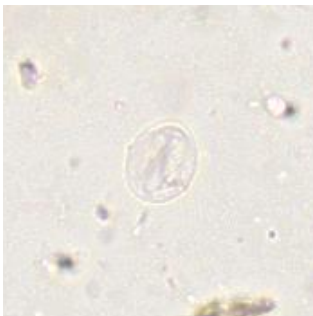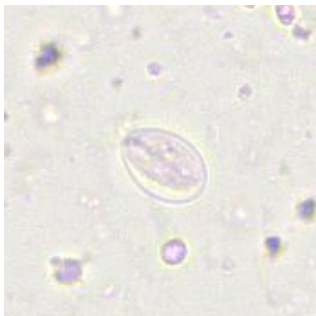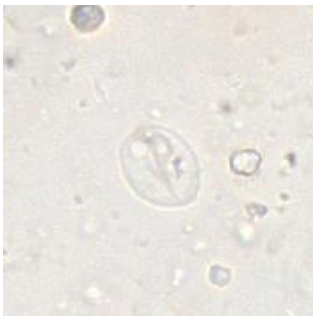AI Fecal - Giardia Report

Summary

Ova/Oocysts	Detected	Counts
Giardia	Yes	16

Comments

Giardia



**Patient ID:**  
**Patient Name:**  
**Test ID:**  
**Birth Date:**  
**Age:** 2 months  
**Species:** Canine  
**Breed:** Schnauzer, Miniature  
**Sex:**  
**Color:** Light Brown  
**Consistency:** 4 - Very moist, loses form, non-segmented

**Clinic/Hospital:**  
**Finalized Date:**

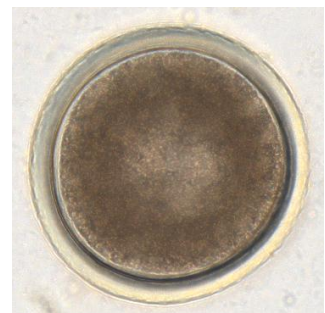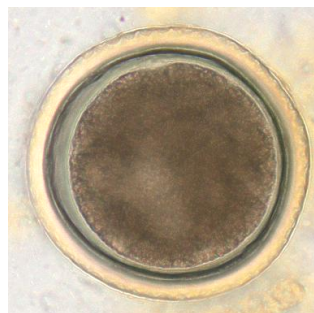
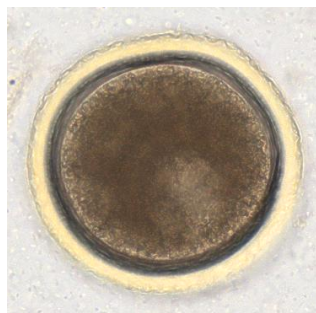
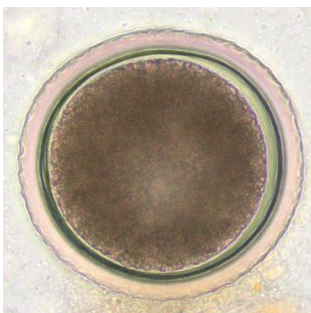
## AI Fecal - Ova/Oocysts Report

### Summary

Ova/Oocysts	Detected	Counts
<i>Ancylostoma</i> (hookworm)	Yes	1135
<i>Cystoisospora</i> (coccidia)	Yes	1603
<i>Giardia</i>	No	0
<i>Taeniidae</i> (tapeworm)	No	0
<i>Toxocara</i> (roundworm)	Yes	197
<i>Trichuris</i> (whipworm)	No	0

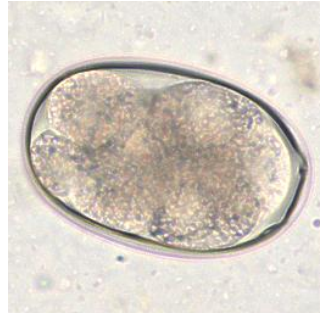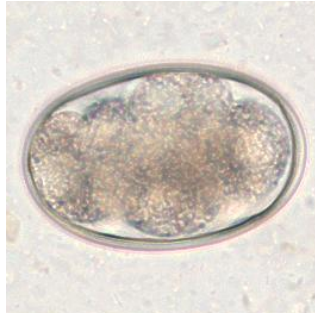
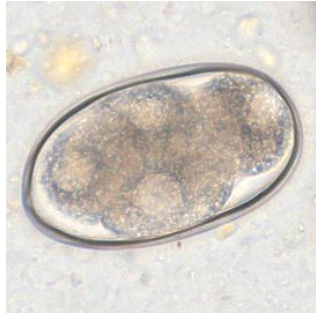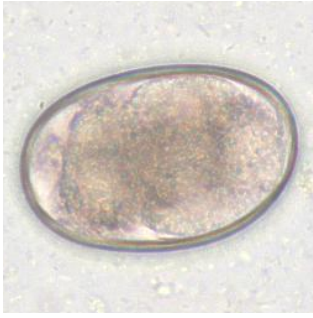### Comments

#### *Toxocara* (roundworm)

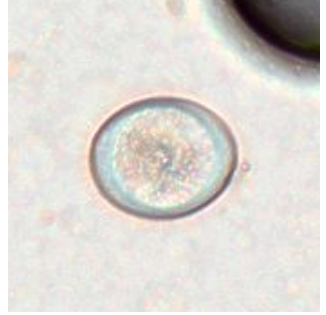
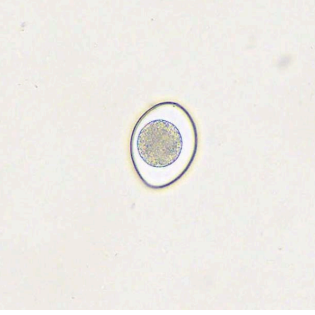
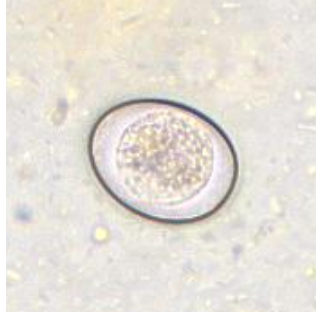
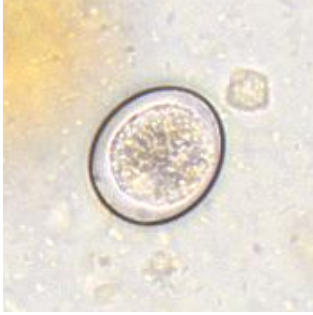




**Ancylostoma (hookworm)**



**Cystoisospora (coccidia)**



Patient ID:

Clinic/Hospital:

Test ID:

Species: **Canine**

Finalized Date:

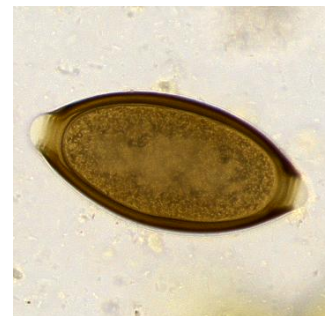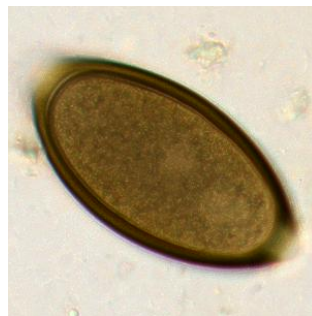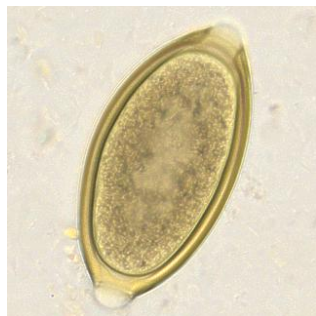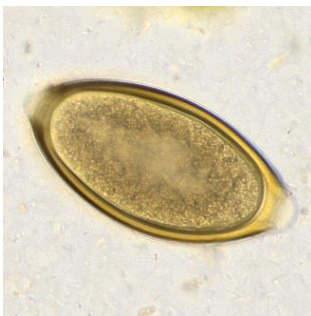## AI Fecal - Ova/Oocysts Report

### Summary

Ova/Oocysts	Detected	Counts
<i>Ancylostoma</i> (hookworm)	No	0
<i>Cystoisospora</i> (coccidia)	No	0
<i>Giardia</i>	No	0
<i>Taeniidae</i> (tapeworm)	No	0
<i>Toxocara</i> (roundworm)	No	0
<i>Trichuris</i> (whipworm)	Yes	16

### Comments

#### *Trichuris* (whipworm)



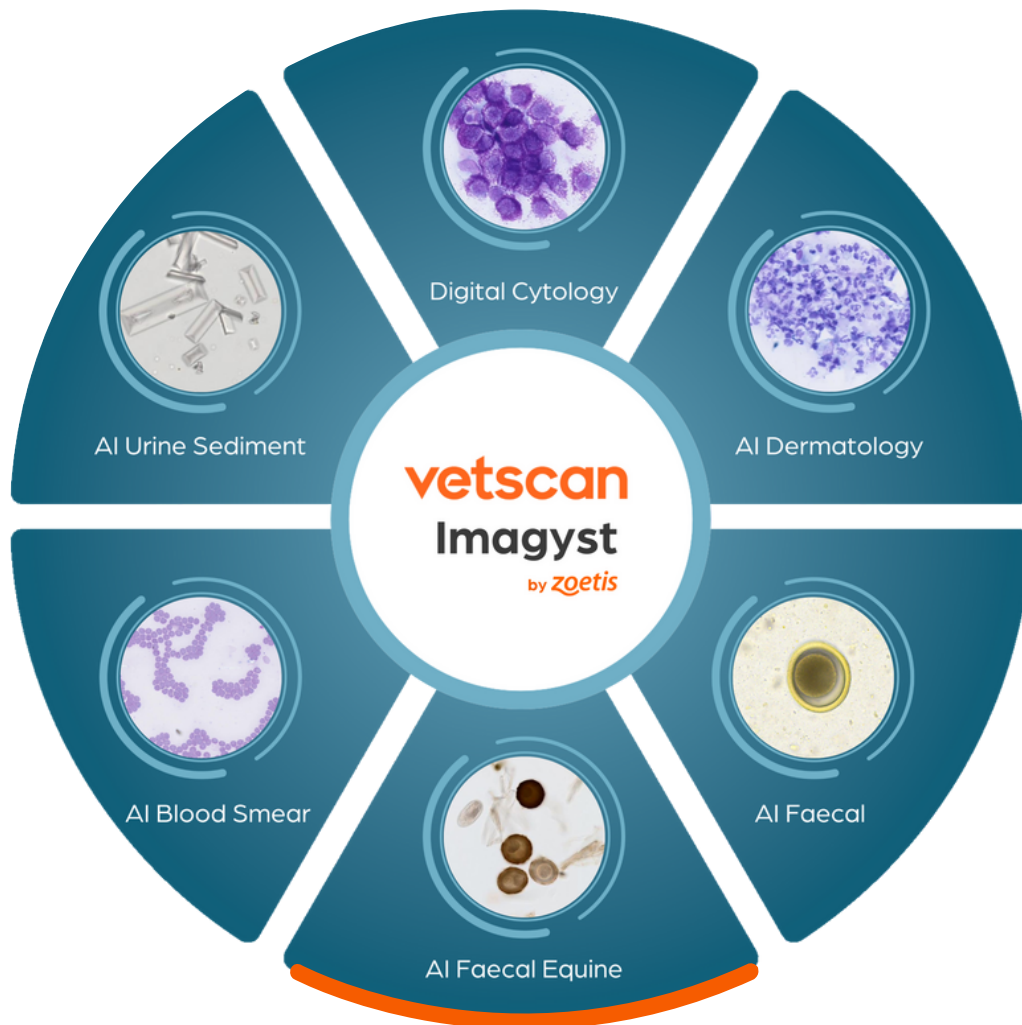ZOETIS DIAGNOSTICS

**vetscan** Imagyst®

# AI Equine Faecal Reports



Part of the unique, multi-application  
Vetscan Imagyst platform from Zoetis



LOOK DEEPER

**zoetis**

Patient ID:		Clinic/Hospital:	
Patient Name:		Finalized Date:	
Test ID:		Flotation Solution:	Sugar (Sheather's)
Species:	Equine		
Color:	Green		
Consistency:	3 - Normal formed		

## AI Equine Fecal Egg Count Report

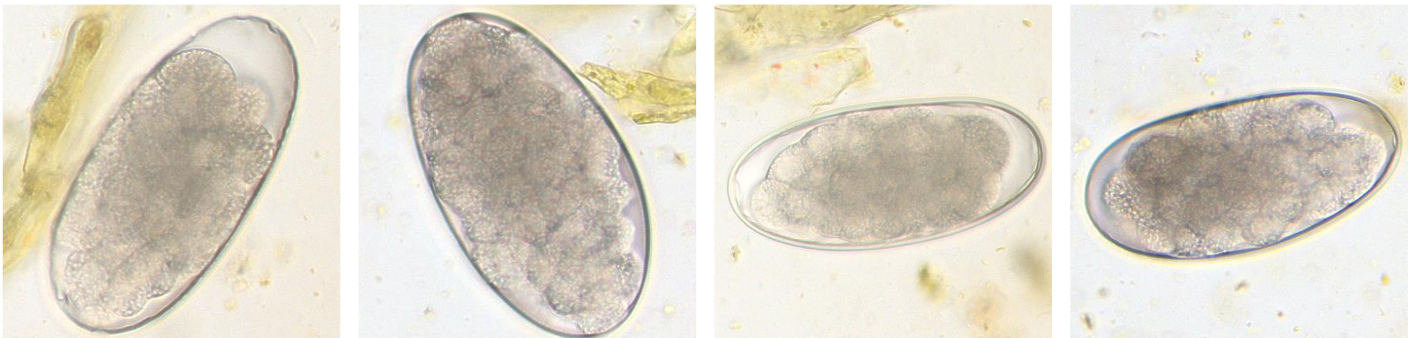
### Summary

Ova/Oocysts	Detected	EPG
<i>Parascaris</i> (roundworm)	No	0
Strongyle	Yes	900

### Comments

0 EPG indicates that no ova were detected on the slide evaluated

### Strongyle





Patient ID:  
Test ID:  
Species: **Equine**

Clinic/Hospital:

Finalized Date: **10/30/2023 8:52 AM CDT**  
Flotation Solution: **No solution specified**

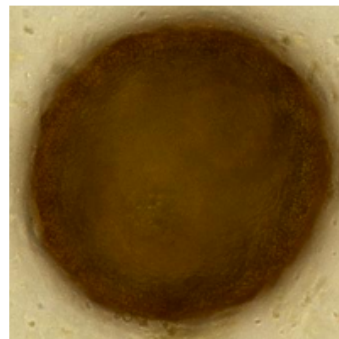
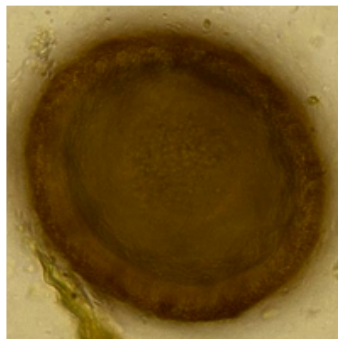
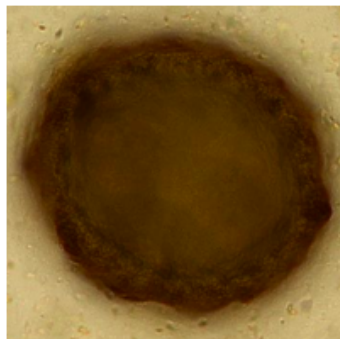
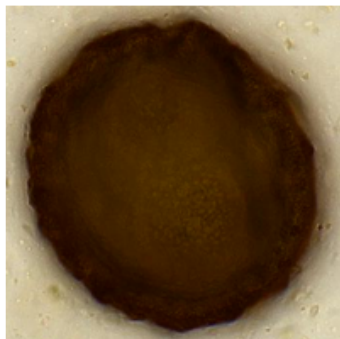
## AI Equine Fecal Egg Count Report

### Summary

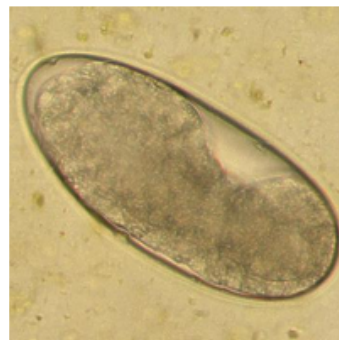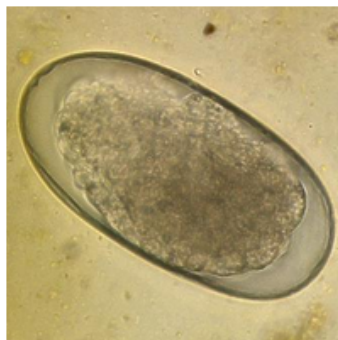
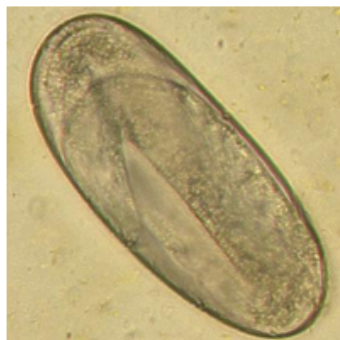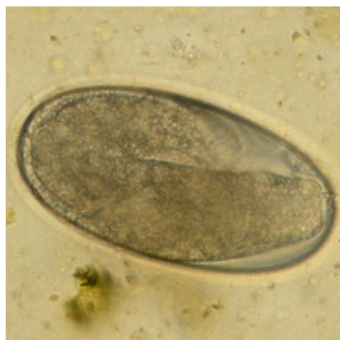Ova/Oocysts	Detected	EPG
<i>Parascaris</i> (roundworm)	Yes	216
Strongyle	Yes	352

### Comments

#### *Parascaris* (roundworm)



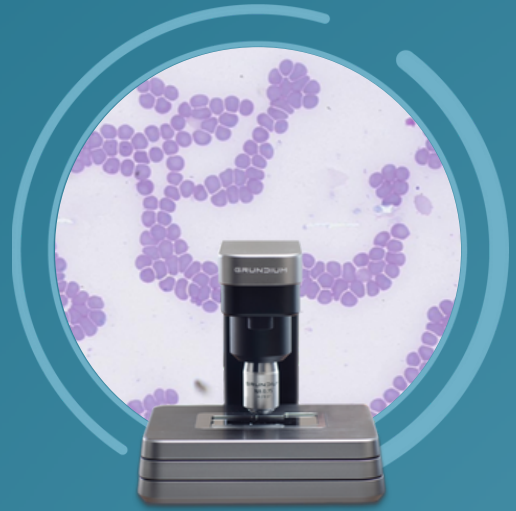
#### Strongyle



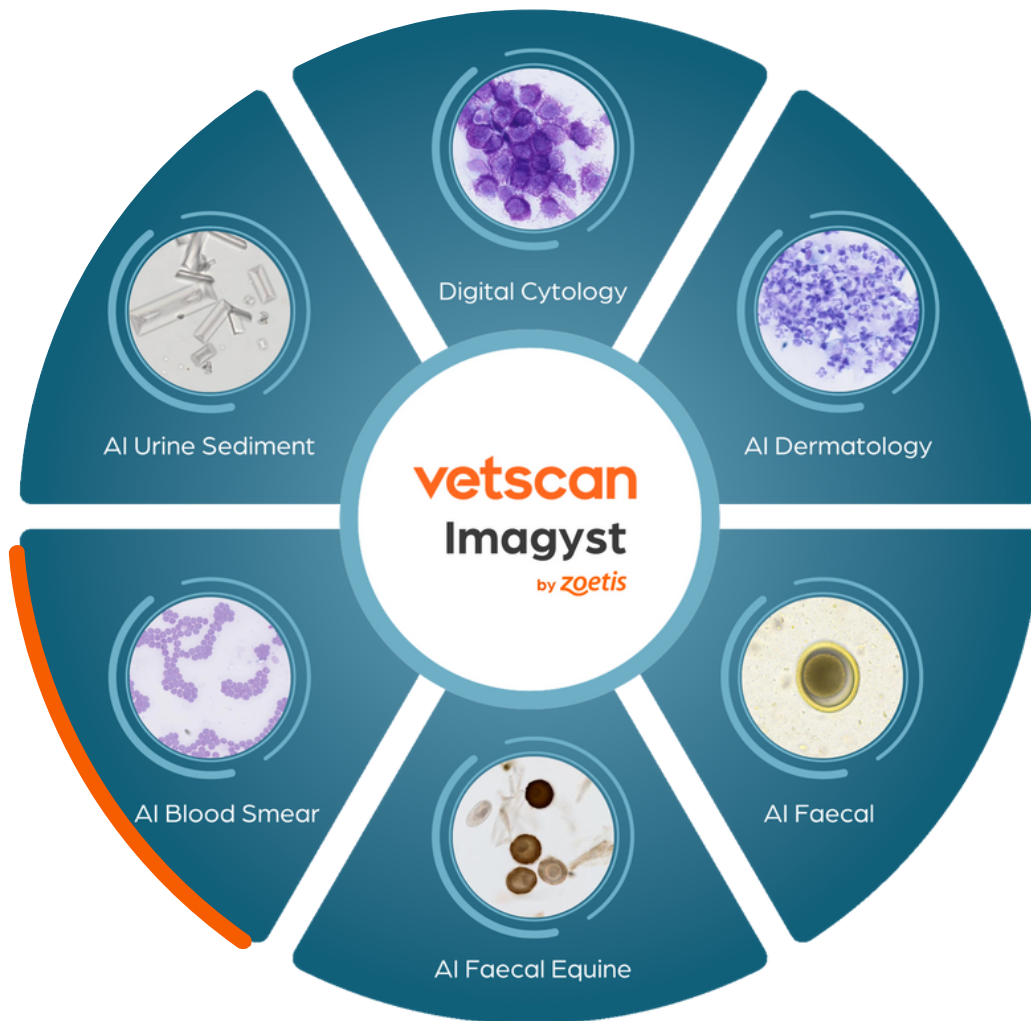ZOETIS DIAGNOSTICS

**vetscan** Imagyst®

# AI Blood Smear Reports



Part of the unique, multi-application  
Vetscan Imagyst platform from Zoetis



LOOK DEEPER

**zoetis**

Patient ID:  
Patient Name:  
Test ID:  
Birth Date: 4/17/2019  
Species: Canine  
Breed: Labrador Retriever  
Gender: Female Spayed

Clinic/Hospital: Veterinary Hospital  
Submitted Date:  
Finalized Date:

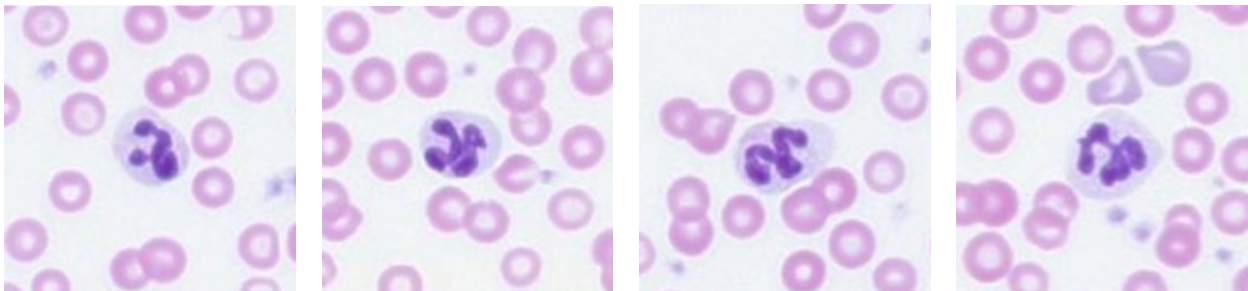
Hematology Evaluation

WBC Differential+

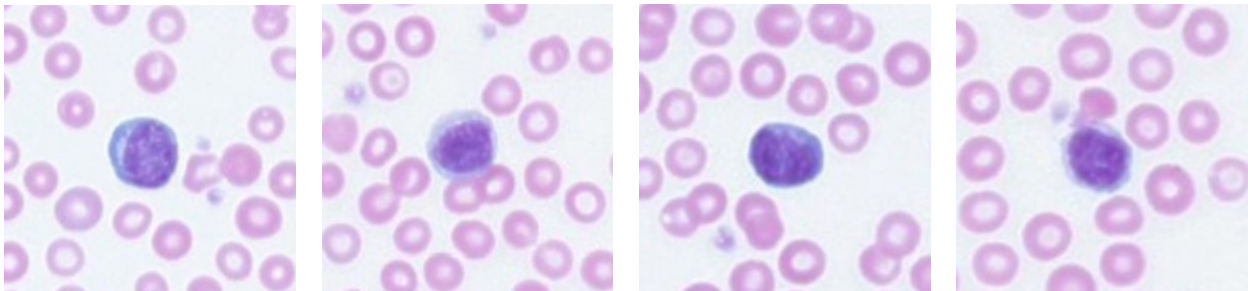
WBC Est. Count	42.90 K/uL		Polychromatophil	450.00 K/uL	
Neutrophil	38.61 K/uL		Nucleated RBC	4.00 / 100 WBC	
Lymphocyte	3.00 K/uL		Platelet	115.70 K/uL	
Monocyte	0.86 K/uL		Medium Aggregated Platelets	Present	
Eosinophil	0.43 K/uL		Large Aggregated Platelets	Present	
Basophil	0.00 K/uL				
Neutrophil %	90.0				
Lymphocyte %	7.0				
Monocyte %	2.0				
Eosinophil %	1.0				
Basophil %	0.0				

White Blood Cell

Neutrophil

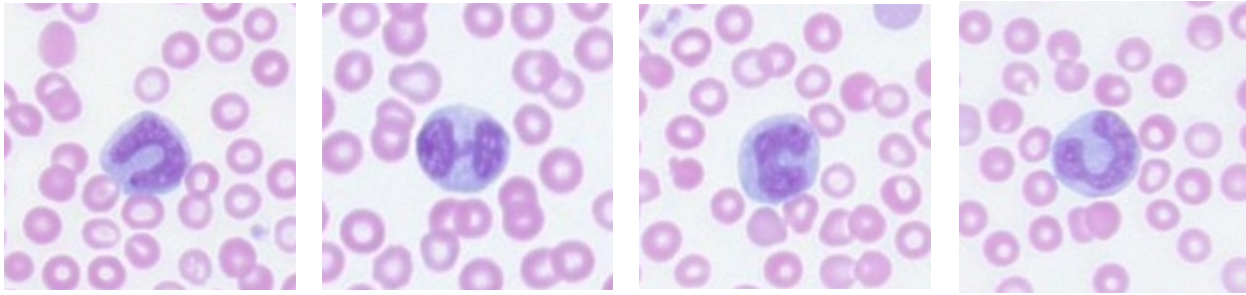


Lymphocyte

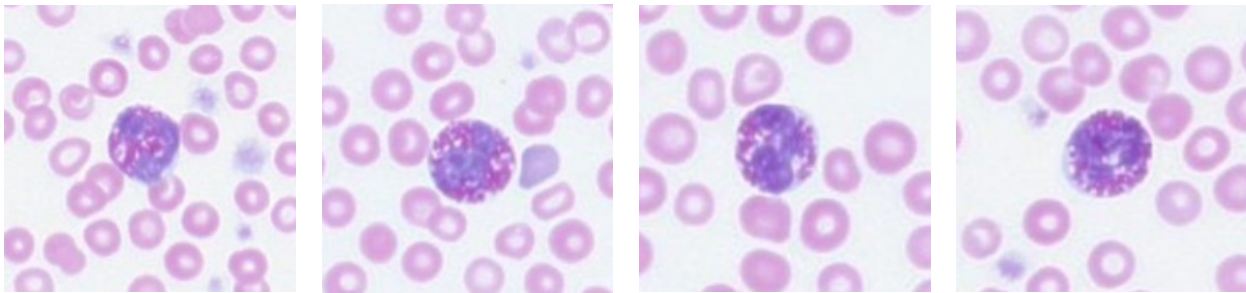




## Monocyte



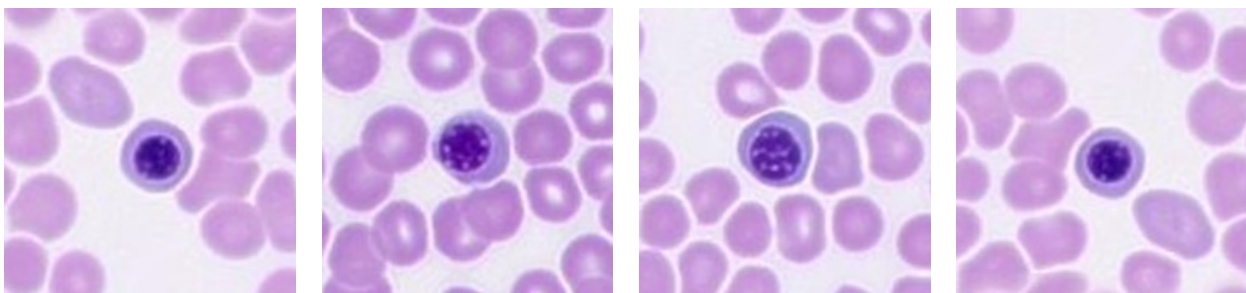
## Eosinophil



---

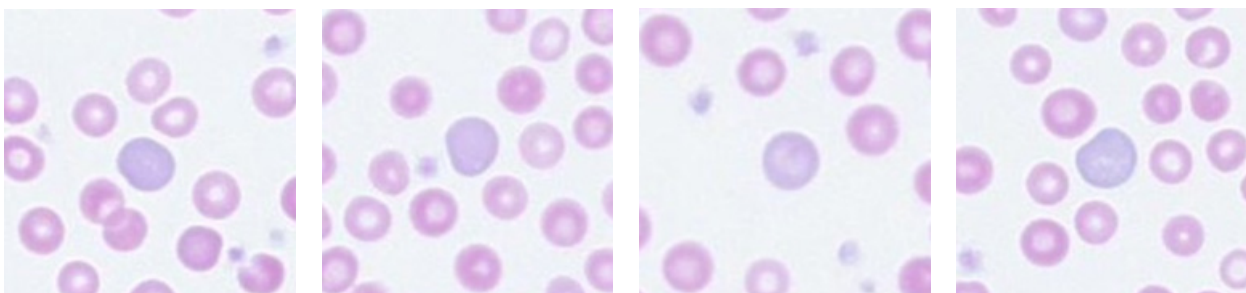
## Particular Red Blood Cells

### Nucleated RBC



---

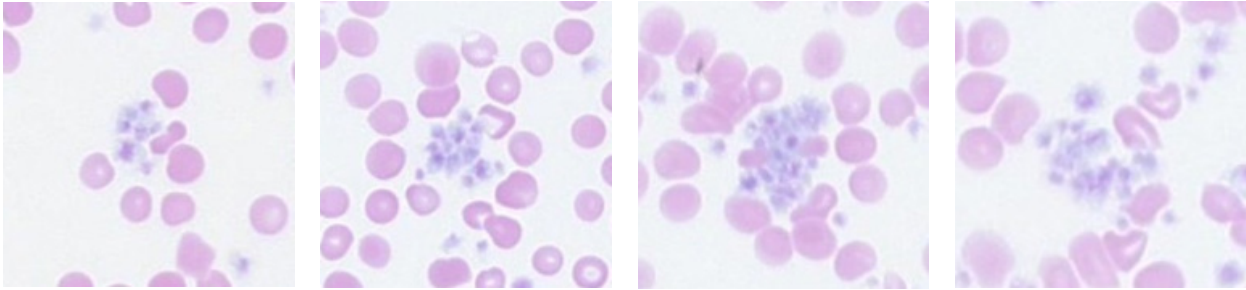
### Polychromatophil



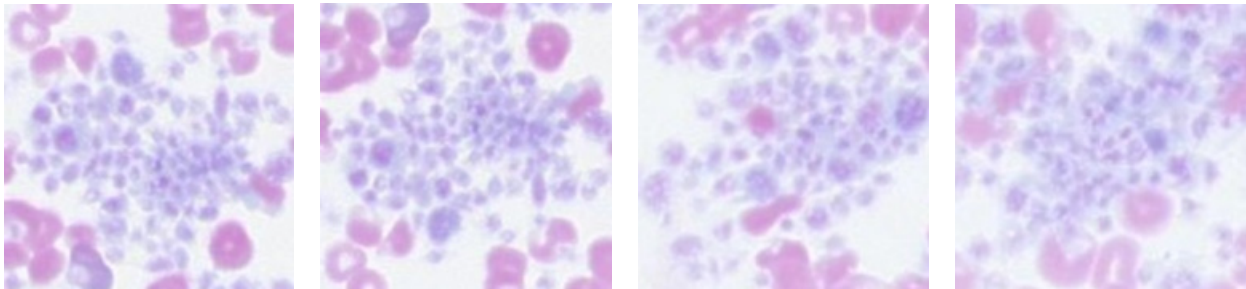


# Platelets

## Medium Aggregated Platelets



## Large Aggregated Platelets



## Comments

**Disclaimer:** This report and the results contained herein relate only to the section(s) of the slide(s) submitted for evaluation as received. Additional material or content present on other sections of the slide(s) or on other slide(s) not submitted for evaluation may compromise the accuracy of the diagnosis.

Patient ID:  
 Patient Name:  
 Test ID:  
 Birth Date: 01/17/2014  
 Species: Feline  
 Breed: DLH  
 Gender: Female Spayed

Clinic/Hospital: Veterinary Hospital  
 Submitted Date:  
 Finalized Date:

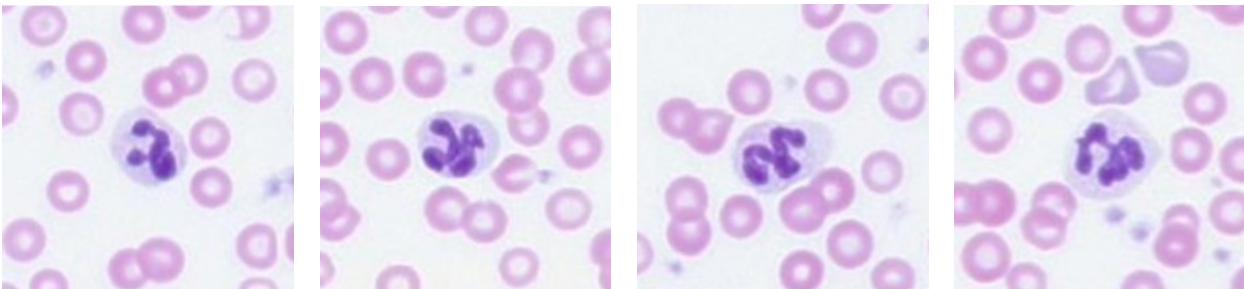
## Hematology Evaluation

### WBC Differential+

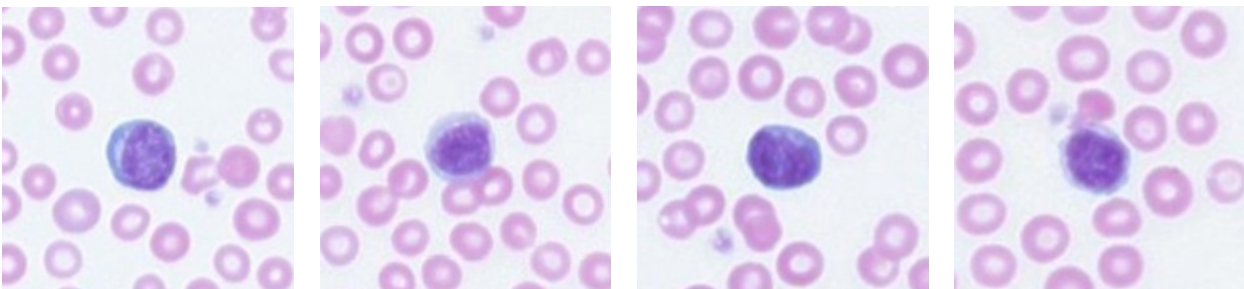
WBC Est. Count	13.0 K/uL		Polychromatophil	6.30 K/uL	
Neutrophil	8.61 K/uL		Nucleated RBC	0.00 / 100 WBC	
Lymphocyte	4.03 K/uL		Platelet	99.0 K/uL	
Monocyte	0.65 K/uL		Medium Aggregated Platelets	Present	
Eosinophil	0.25 K/uL		Large Aggregated Platelets	Present	
Basophil	0.00 K/uL				
Neutrophil %	62.0				
Lymphocyte %	31.0				
Monocyte %	5.0				
Eosinophil %	2.0				
Basophil %	0.0				

## White Blood Cell

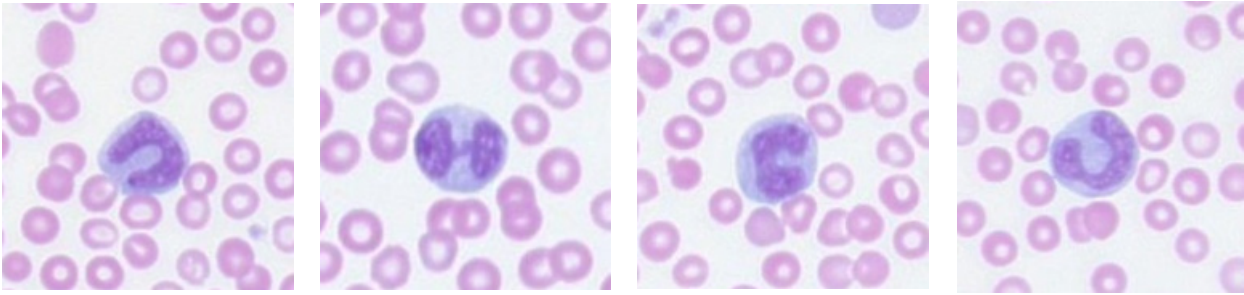
### Neutrophil



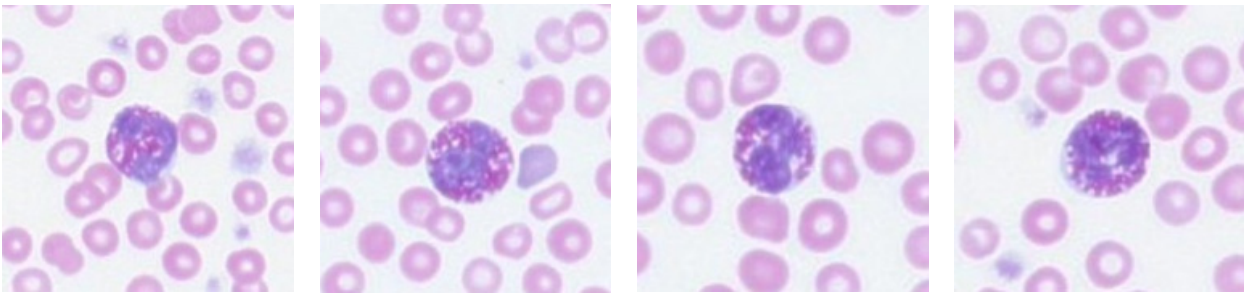
### Lymphocyte



## Monocyte



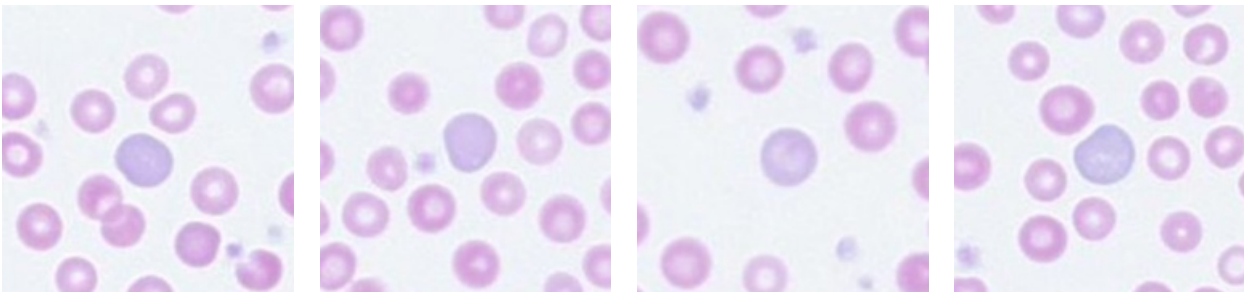
## Eosinophil



---

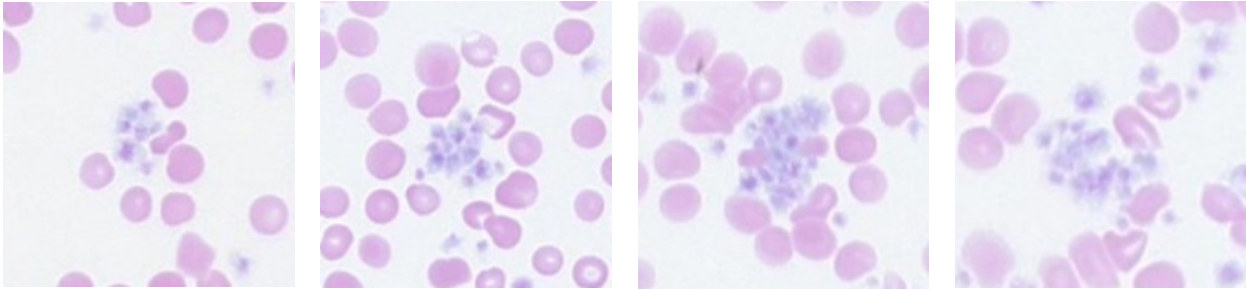
## Particular Red Blood Cells

### Polychromatophil

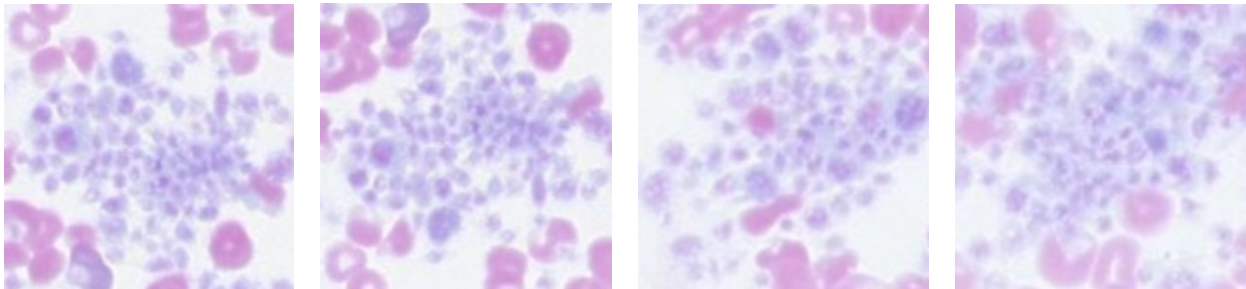


# Platelets

## Medium Aggregated Platelets



## Large Aggregated Platelets



## Comments

**Disclaimer:** This report and the results contained herein relate only to the section(s) of the slide(s) submitted for evaluation as received. Additional material or content present on other sections of the slide(s) or on other slide(s) not submitted for evaluation may compromise the accuracy of the diagnosis.



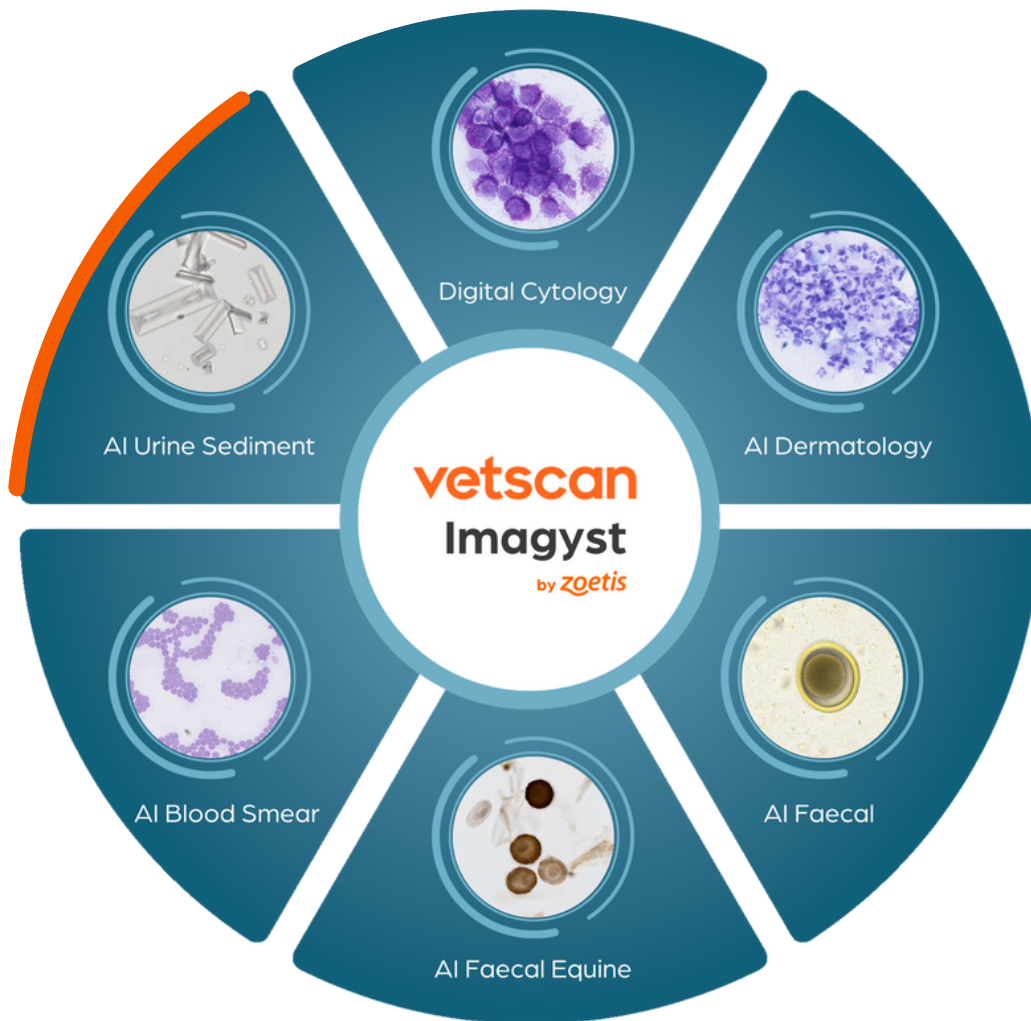ZOETIS DIAGNOSTICS

**vetscan** Imagyst®

# AI Urine Sediment Reports



Part of the unique, multi-application  
Vetscan Imagyst platform from Zoetis



LOOK DEEPER

**zoetis**

Patient ID: 000000  
 Patient Name:  
 Test ID: 0000000  
 Species: Feline

Clinic/Hospital: Veterinary Hospital  
 Finalized Date:

## AI Urine Report

### Sample Details

Urine Retrieval Technique	Cystocentesis	Color before Centrifugation	Yellow
Clarity	Cloudy	Color after Centrifugation	Same as Pre-Centrifugation
Urine Volume	3 mL	Dilution Ratio	No Dilution
pH	7.0	Collection Time	0 - 30 minutes
USG	1.045	Storage Conditions	Never Refrigerated

### Blood Cells

Type	Semi-Quant (per HPF)
RBCs	None to rare (0-5)
WBCs	Moderate (21-50)

### Crystals

Type	Semi-Quant (per HPF)
Struvite	None to rare (0-1)
Calcium Oxalate Dihydrate	None to rare (0-1)

### Bacteria

Type	Semi-Quant (per HPF)
Cocci	3+
Rods	None to rare

### Epithelial Cells

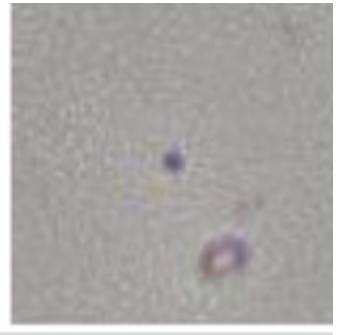

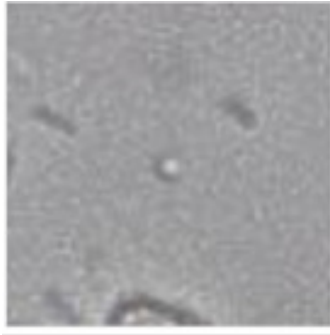
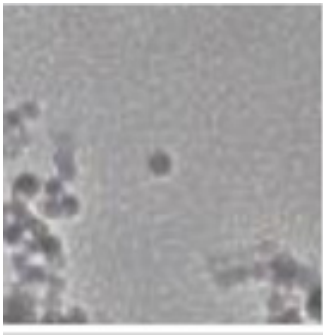
Type	Semi-Quant (per HPF)
Squamous Epithelial Cells	Few (1-4)
Other Epithelial Cells	None to rare (0-1)

### Casts



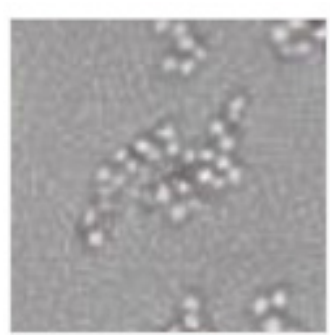
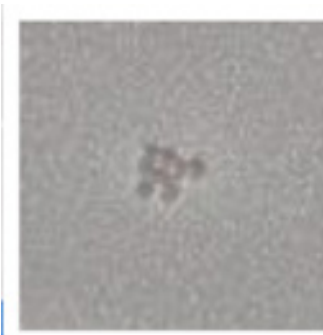
Type	Semi-Quant (per LPF)
Hyaline Cast	None to rare (0- <1)
Non-Hyaline Cast	None to rare (0- <1)

## Bacteria

### Cocci

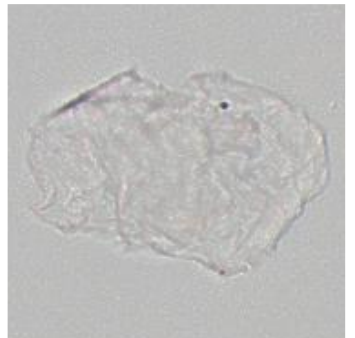
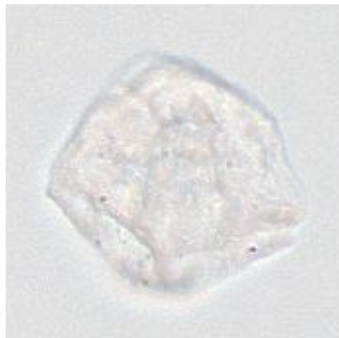
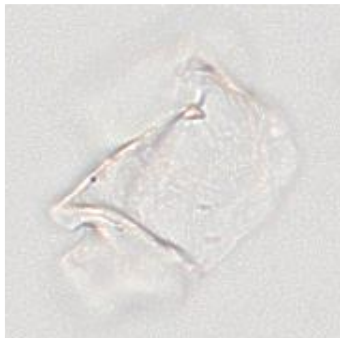



### Cocci Clusters & Chains



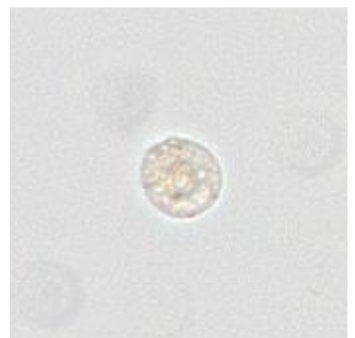
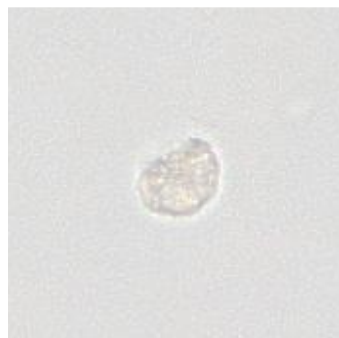
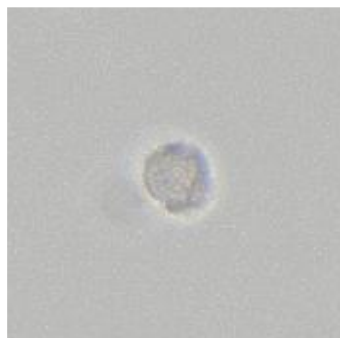
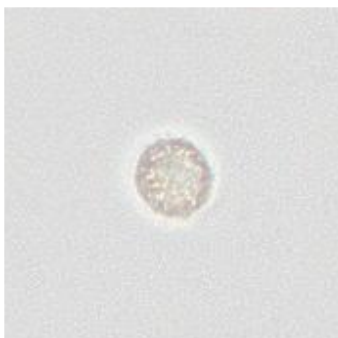## Epithelial Cells

### Squamous Epithelial Cells



## Blood Cells

### WBCs



Patient ID: 00000  
 Patient Name:  
 Test ID: 0000000  
 Species: Feline

Clinic/Hospital: Veterinary Hospital  
 Finalized Date:

## AI Urine Report

### Sample Details

Urine Retrieval Technique	Cystocentesis	Color before Centrifugation	Light Yellow
Clarity	Clear	Color after Centrifugation	Same as Pre-Centrifugation
Urine Volume	1 mL	Dilution Ratio	No Dilution
pH	7	Collection Time	0 - 30 minutes
USG	1.012	Storage Conditions	Never Refrigerated

### Blood Cells

Type	Semi-Quant (per HPF)
RBCs	None to rare (0-5)
WBCs	Few (6-20)

### Crystals

Type	Semi-Quant (per HPF)
Struvite	None to rare (0-1)
Calcium Oxalate Dihydrate	None to rare (0-1)

### Bacteria

Type	Semi-Quant (per HPF)
Cocci	1+
Rods	None to rare

### Epithelial Cells

Type	Semi-Quant (per HPF)
Squamous Epithelial Cells	None to rare (0-1)
Other Epithelial Cells	None to rare (0-1)

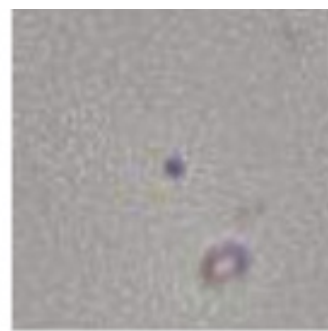
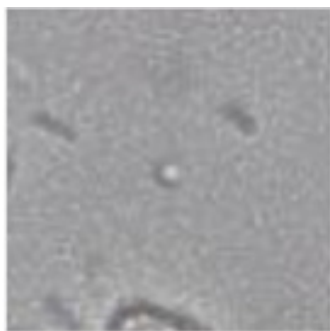
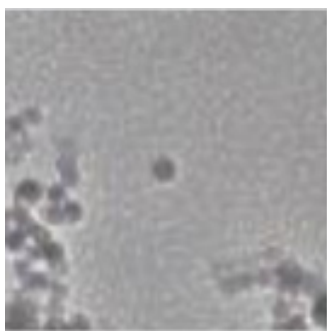
### Casts

Type	Semi-Quant (per LPF)
Hyaline Cast	Moderate (5-10)
Non-Hyaline Cast	None to rare (0- <1)


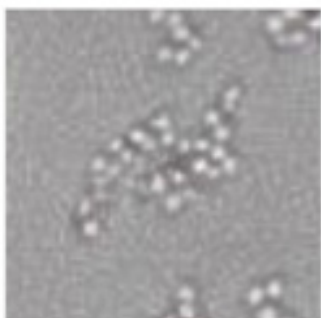


## Bacteria

### Cocci

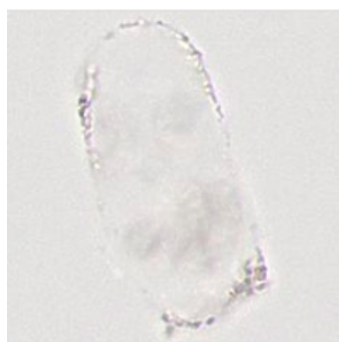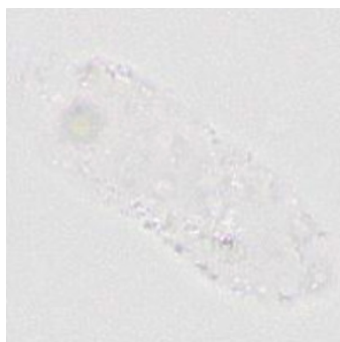
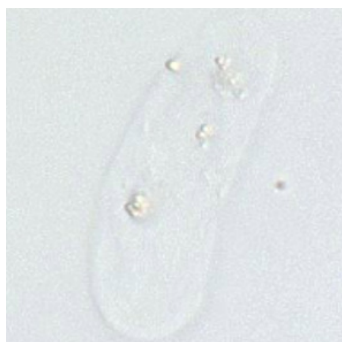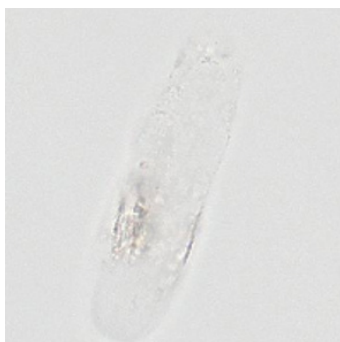


### Cocci Clusters & Chains



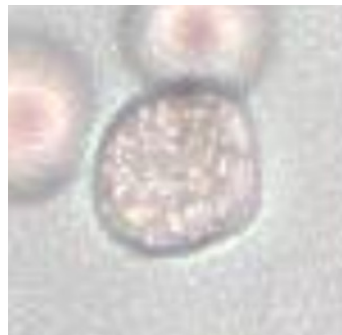
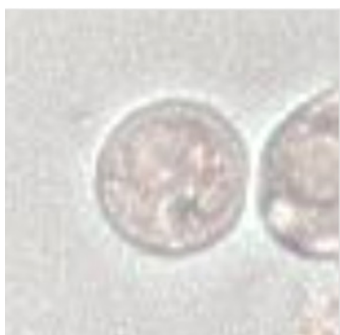## Casts

### Hyaline Cast



## Blood Cells

### WBCs



Patient ID: 000000  
 Patient Name:  
 Test ID: 0000000  
 Species: Canine

Clinic/Hospital: Veterinary Hospital  
 Finalized Date:

## AI Urine Report

### Sample Details

Urine Retrieval Technique	Free Catch	Color before Centrifugation	Red
Clarity	Clear	Color after Centrifugation	Yellow
Urine Volume	3 mL	Dilution Ratio	1:2
pH	7.5	Collection Time	0 - 30 minutes
USG	1.040	Storage Conditions	Never Refrigerated

### Blood Cells

Type	Semi-Quant (per HPF)
RBCs	Many (>100)
WBCs	Many (>50)

### Crystals

Type	Semi-Quant (per HPF)
Struvite	None to rare (0-1)
Calcium Oxalate Dihydrate	None to rare (0-1)

### Bacteria

Type	Semi-Quant (per HPF)
Cocci	None to rare
Rods	3+

### Epithelial Cells

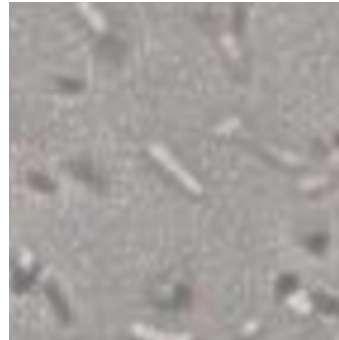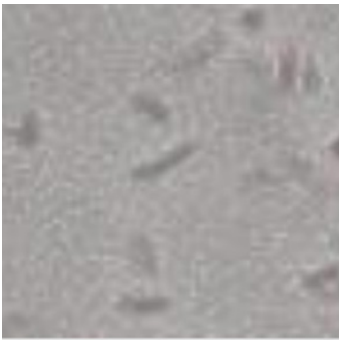Type	Semi-Quant (per HPF)
Squamous Epithelial Cells	None to rare (0-1)
Other Epithelial Cells	None to rare (0-1)

### Casts

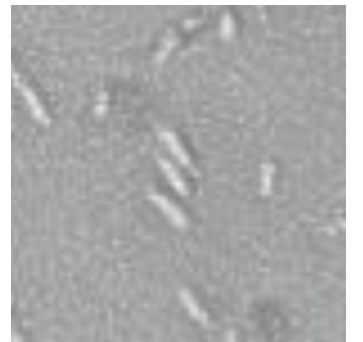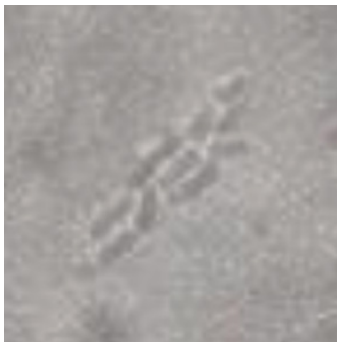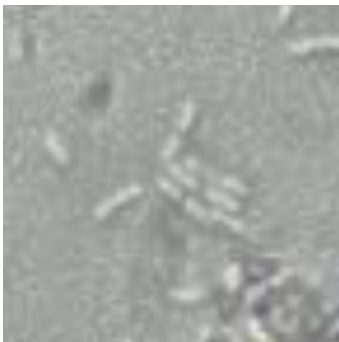Type	Semi-Quant (per LPF)
Hyaline Cast	None to rare (0- <1)
Non-Hyaline Cast	None to rare (0- <1)

## Bacteria

### Rods

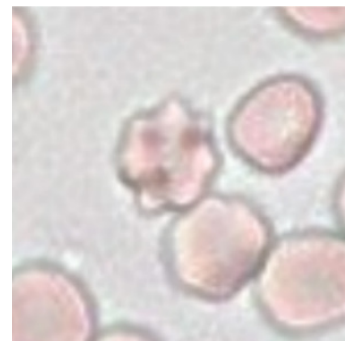
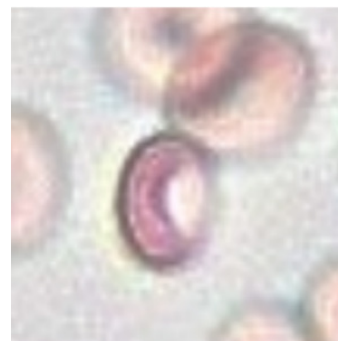
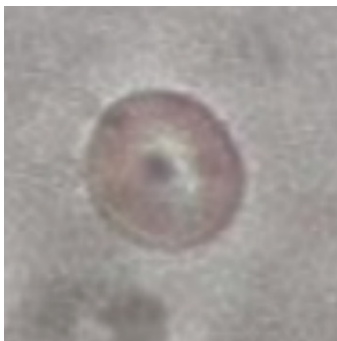
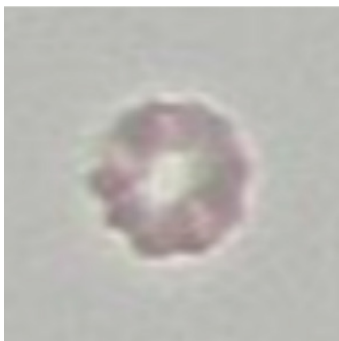

### Rods Clusters & Chains

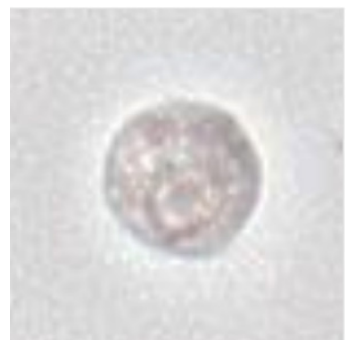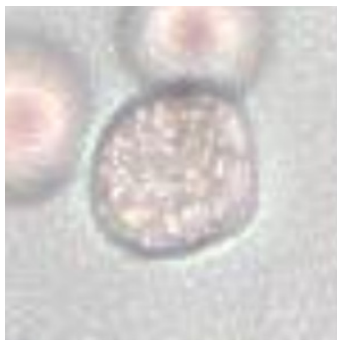

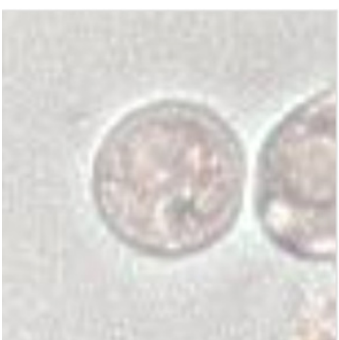
## Blood Cells

### RBCs



### WBCs



Patient ID: 000000  
 Patient Name:  
 Test ID: 000000  
 Species: Canine

Clinic/Hospital: Veterinary Hospital  
 Finalized Date:

## AI Urine Report

### Sample Details

Urine Retrieval Technique	Catheterization	Color before Centrifugation	Yellow
Clarity	Clear	Color after Centrifugation	Same as Pre-Centrifugation
Urine Volume	3 mL	Dilution Ratio	No Dilution
pH	7.0	Collection Time	1 - 4 hours
USG	1.037	Storage Conditions	Refrigerated

### Blood Cells

Type	Semi-Quant (per HPF)
RBCs	None to rare (0-5)
WBCs	None to rare (0-5)

### Crystals

Type	Semi-Quant (per HPF)
Struvite	Few (2-4)
Calcium Oxalate Dihydrate	None to rare (0-1)

### Bacteria

Type	Semi-Quant (per HPF)
Cocci	None to rare
Rods	None to rare

### Epithelial Cells

Type	Semi-Quant (per HPF)
Squamous Epithelial Cells	None to rare (0-1)
Other Epithelial Cells	Many (>10)


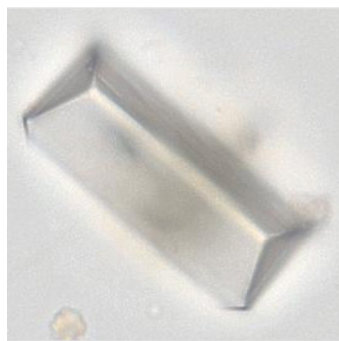
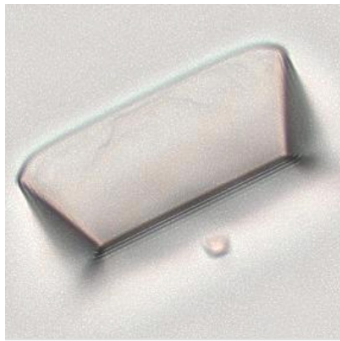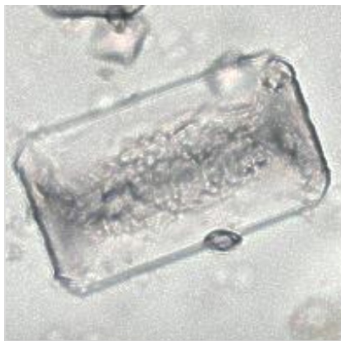
### Casts

Type	Semi-Quant (per LPF)
Hyaline Cast	None to rare (0- <1)
Non-Hyaline Cast	None to rare (0- <1)



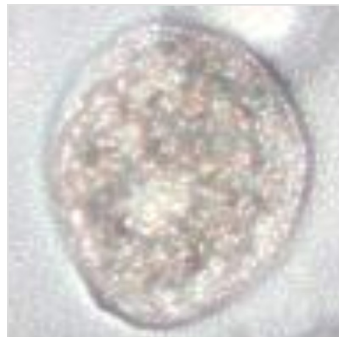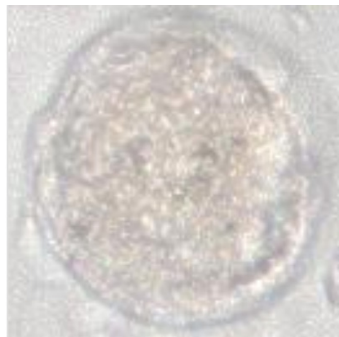
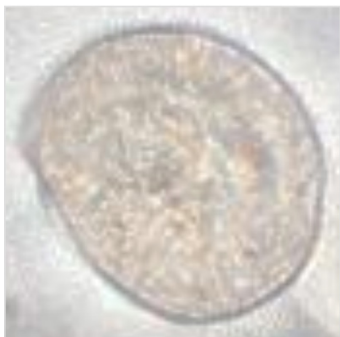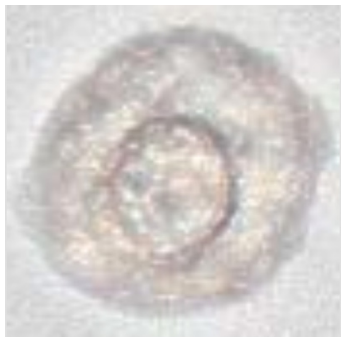## Crystals

### Struvite

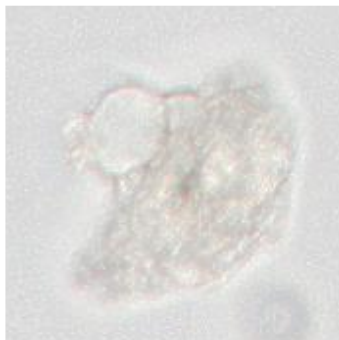
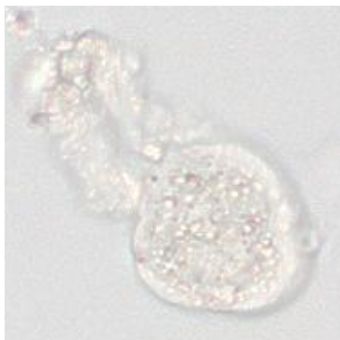
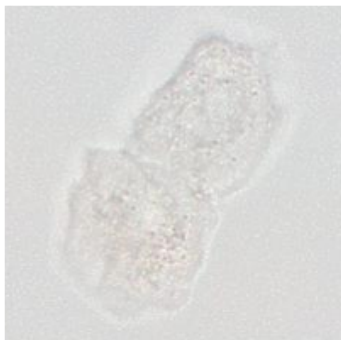


## Epithelial Cells

### Other Epithelial Cells



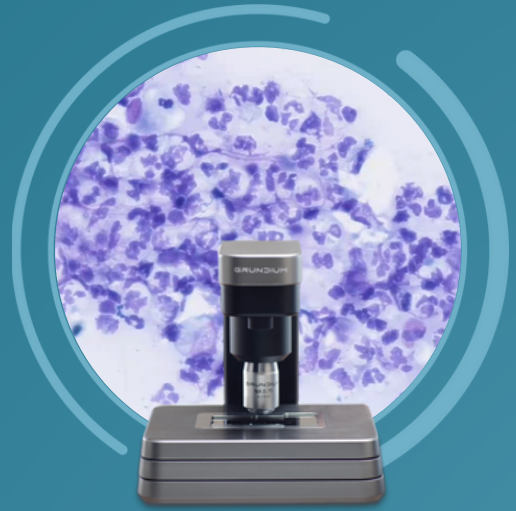
### Other Epithelial Cell Cluster



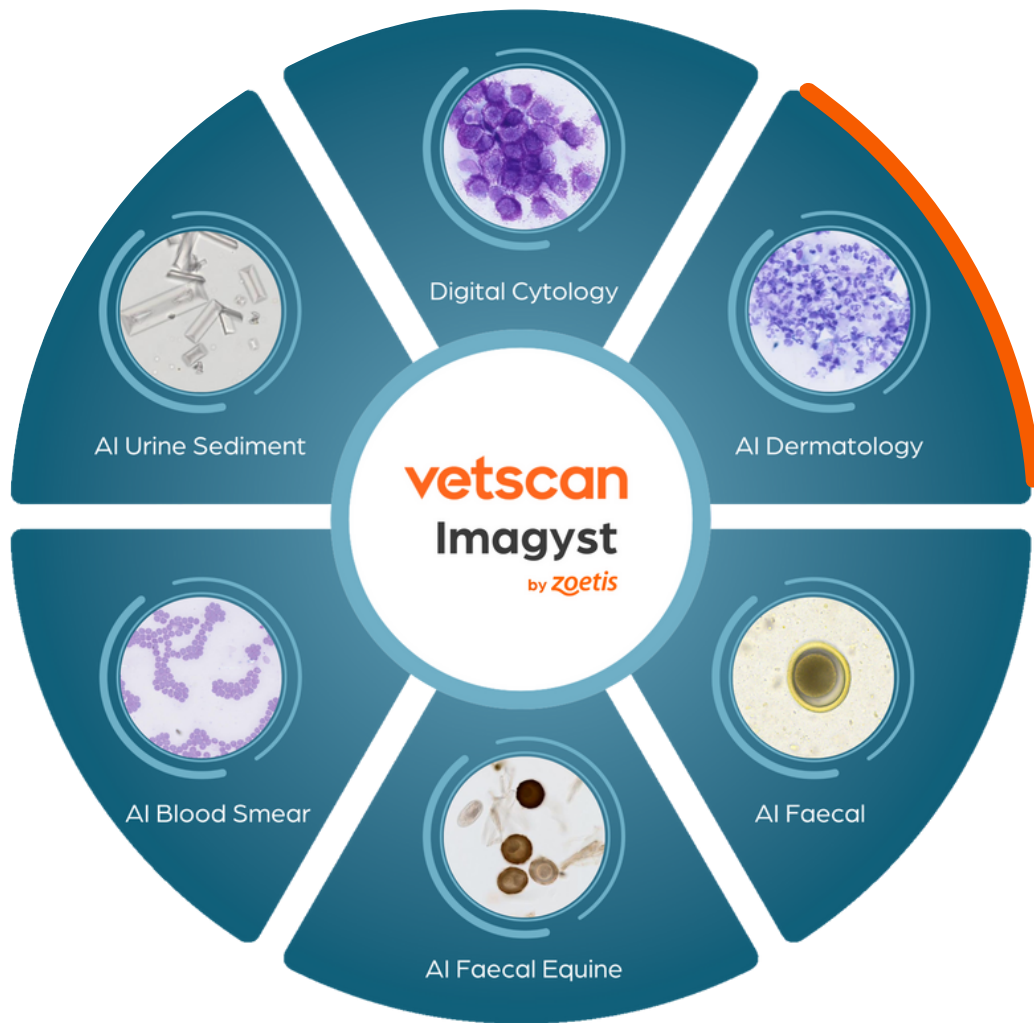ZOETIS DIAGNOSTICS

**vetscan** Imagyst®

# AI Dermatology Reports



Part of the unique, multi-application  
Vetscan Imagyst platform from Zoetis



LOOK DEEPER

**zoetis**

Patient ID:  
Patient Name:  
Test ID:  
Species: Canine

Clinic/Hospital: Veterinary Hospital  
Finalized Date:

AI Dermatology Cytological Evaluation

Left Ear

Bacteria & Yeast	Presence
Bacteria - Rods	3+
Bacteria - Cocci	None to Rare
Yeast - <i>Malassezia</i>	None to Rare

Inflammatory WBC	Detected
Neutrophils	Yes
Neutrophils w Bacteria	Yes
Macrophages	No
Lymphocytes	No
Eosinophils	No

Blood Present: ✖ No

Right Ear

Bacteria & Yeast	Presence
Bacteria - Rods	2+
Bacteria - Cocci	None to Rare
Yeast - <i>Malassezia</i>	1+

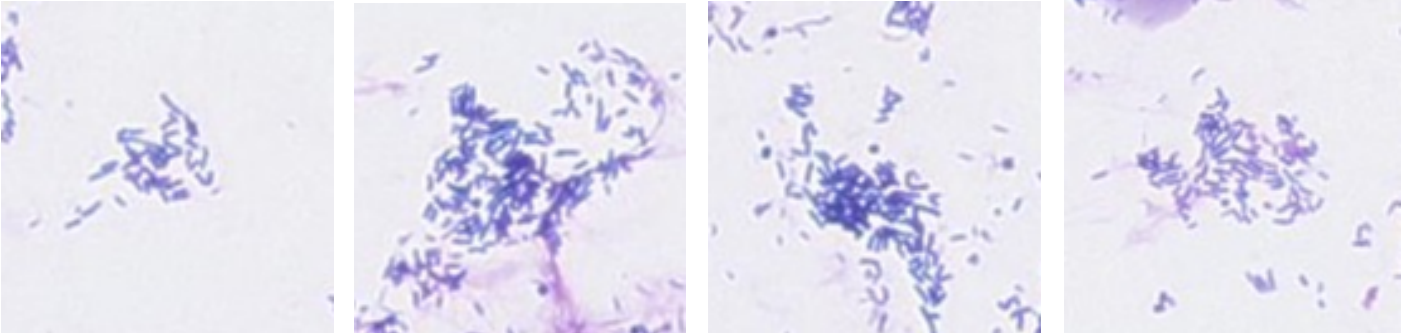
Inflammatory WBC	Detected
Neutrophils	Yes
Neutrophils w Bacteria	Yes
Macrophages	No
Lymphocytes	Yes
Eosinophils	No

Blood Present: ✖ No

Left Ear

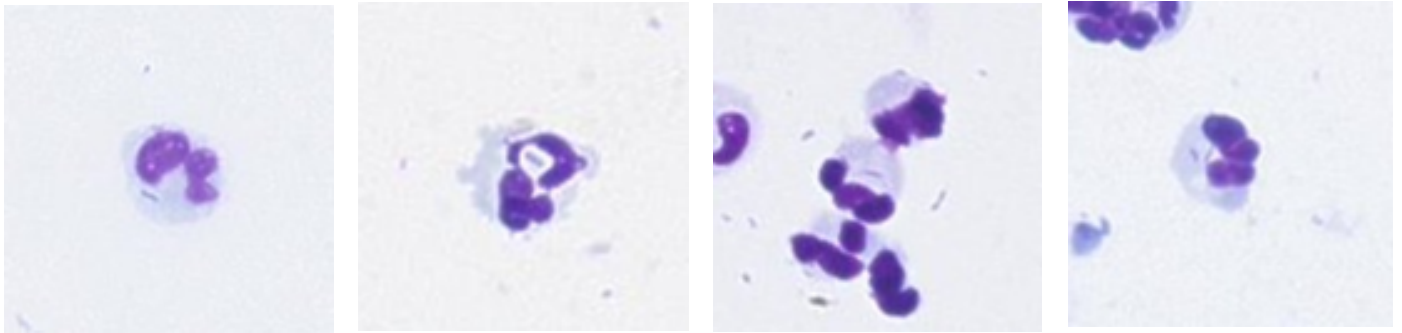
Bacteria

Rods



## Inflammatory WBC

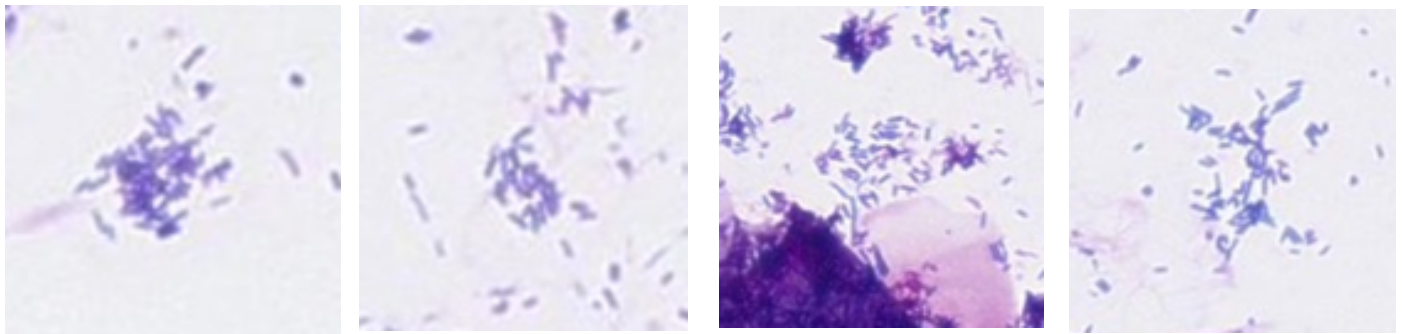
### Neutrophils with Bacteria



## Right Ear

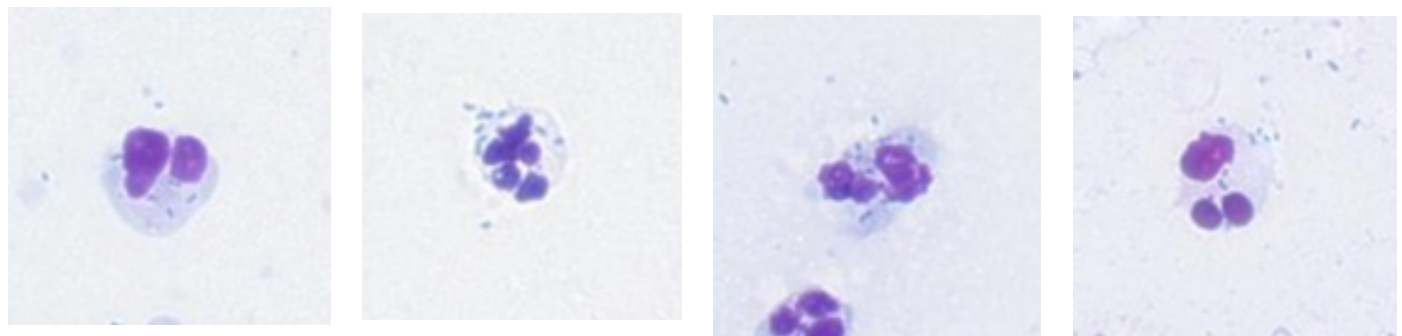
### Bacteria

#### Rods



## Inflammatory WBC

### Neutrophils with Bacteria



### *Malassezia*





Patient ID:

Patient Name:

Test ID:

Species: **Canine**

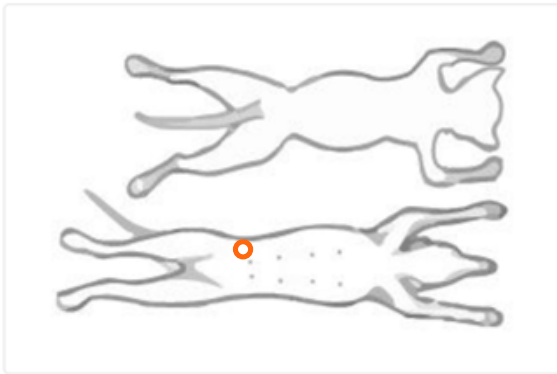
Clinic/Hospital: **Veterinary Hospital**

Finalized Date:

## AI Dermatology Cytological Evaluation

### Site Location

**Abdomen**



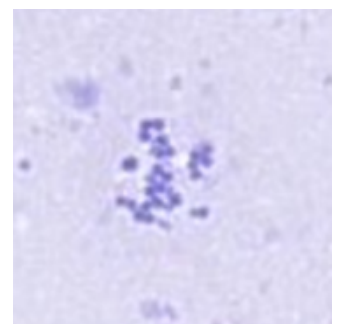
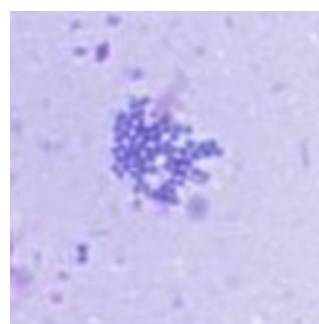
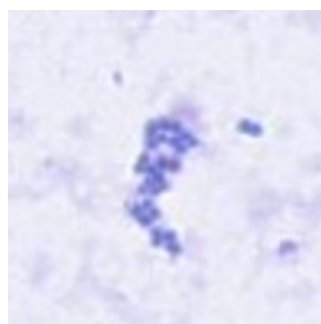
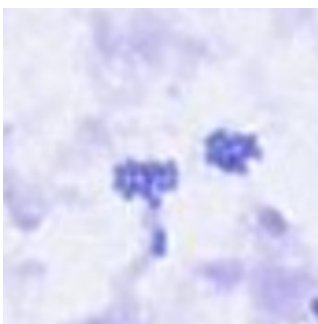
Bacteria & Yeast	Presence
Bacteria - Rods	None to Rare
Bacteria - Cocci	3+
Yeast - <i>Malassezia</i>	None to Rare

Inflammatory WBC	Detected
Neutrophils	Yes
Neutrophils w Bacteria	Yes
Macrophages	No
Lymphocytes	No
Eosinophils	No

**Blood Present: No**

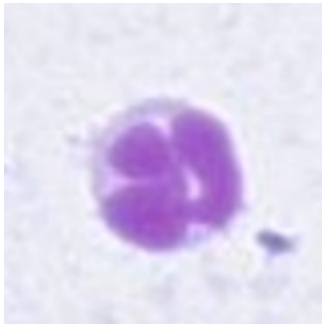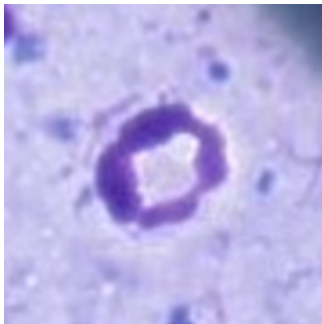
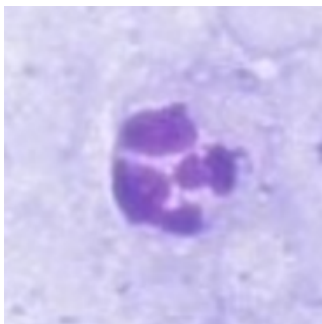
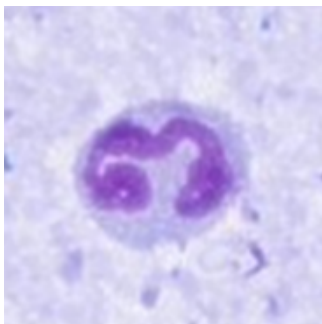
### Bacteria & Yeast

**Cocci**

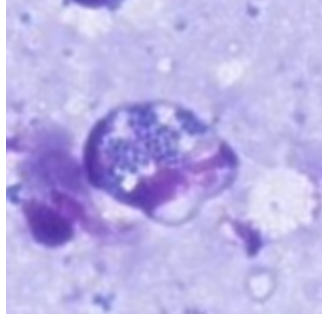
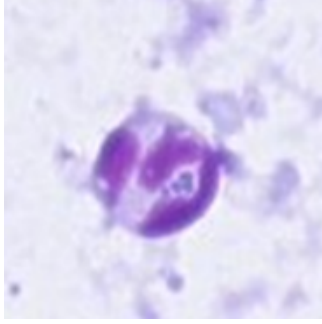
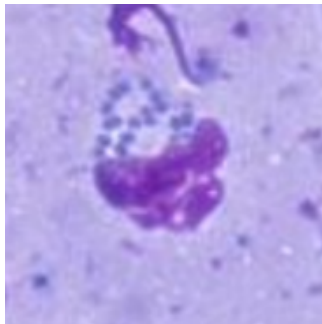
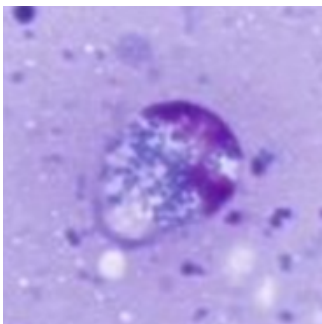


**Inflammatory WBC**

**Neutrophils**



**Containing Bacteria**

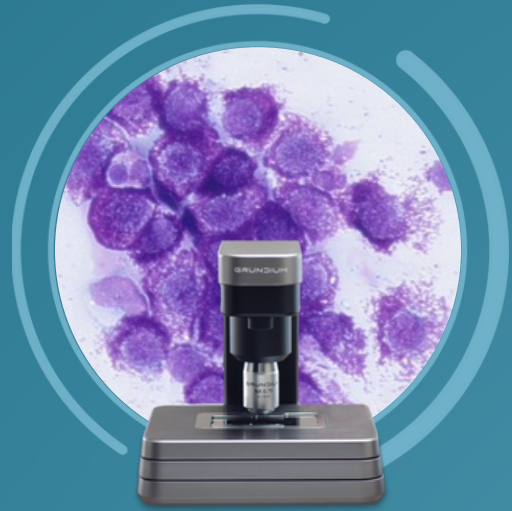


**Comments**

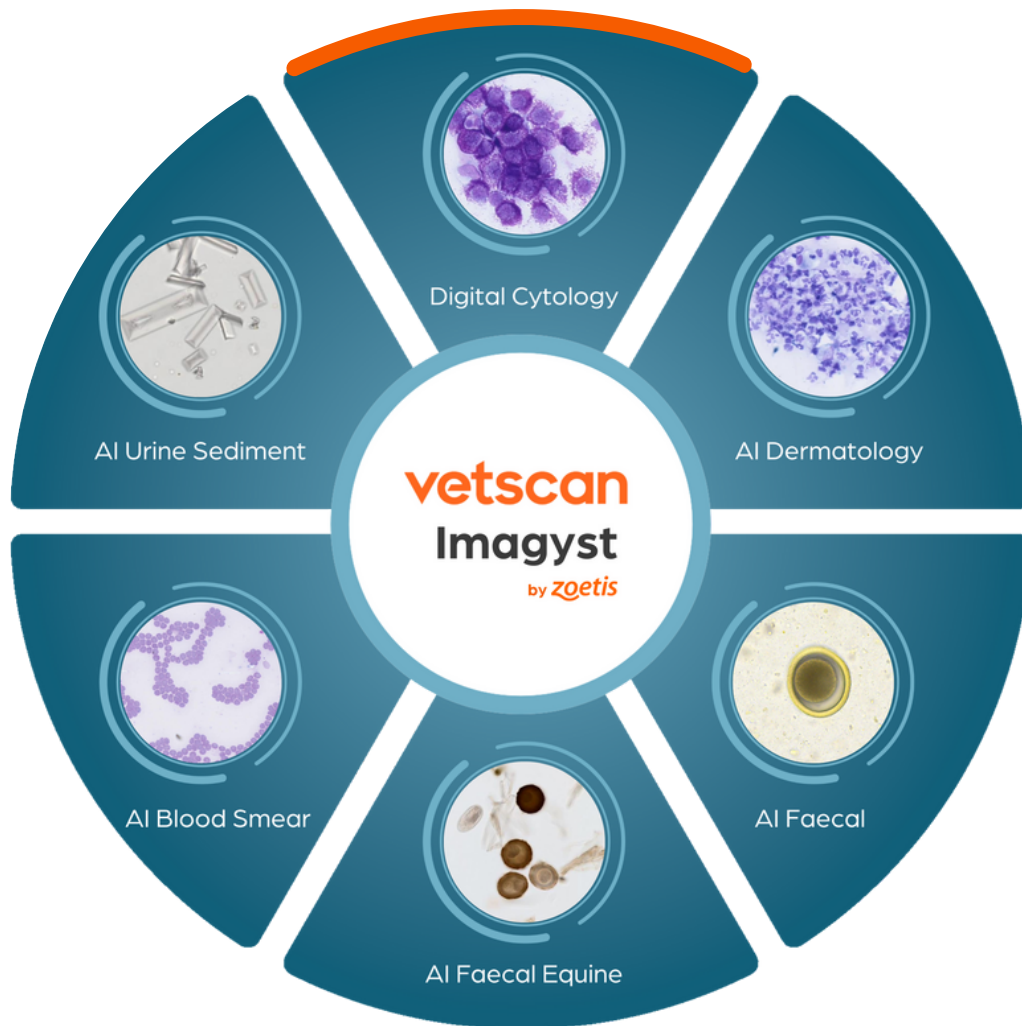ZOETIS DIAGNOSTICS

**vetscan** Imagyst®

# Digital Cytology Reports



Part of the unique, multi-application  
Vetscan Imagyst platform from Zoetis



LOOK DEEPER

**zoetis**

<b>Patient ID:</b>		<b>Clinic/Hospital:</b>	
<b>Patient Name:</b>		<b>Submitted Date:</b>	<b>4/x/2023 9:24 AM PDT</b>
<b>Test ID:</b>		<b>Finalized Date:</b>	<b>4/x/2023 10:14 AM PDT</b>
<b>Birth Date:</b>			
<b>Age:</b>	<b>15 years</b>		
<b>Species:</b>	<b>Feline</b>		
<b>Breed:</b>	<b>DSH</b>		
<b>Sex:</b>	<b>Male Neutered</b>		

## Cytologic Evaluation

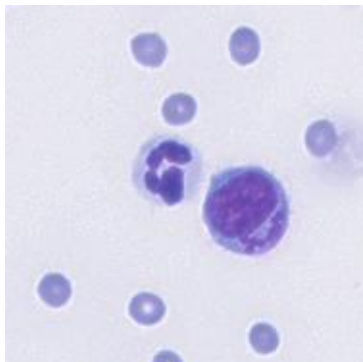
### Clinical History

Anorexia, lethargy, elevated liver enzymes, mild fever. Ultrasound shows bowel mass, evidence of pancreatitis, mild hepatomegaly. Mild ascites, sample is of abdominal effusion.

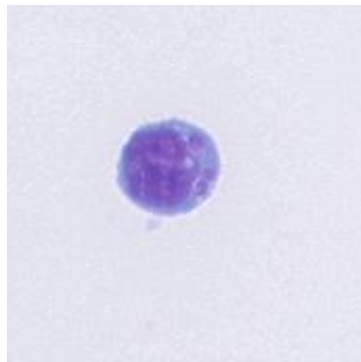
### Abdominal Effusion Site 1 of 1

Cytology: Fluid Analysis

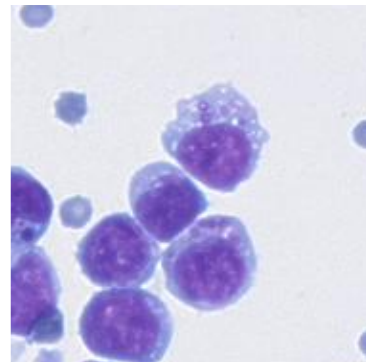
Fluid Detail	Result
Color	Straw
Clarity	Clear
Flocculent Material	No
Source	Peritoneal Effusion
PCV	-



Capture 289575777  
Report Region

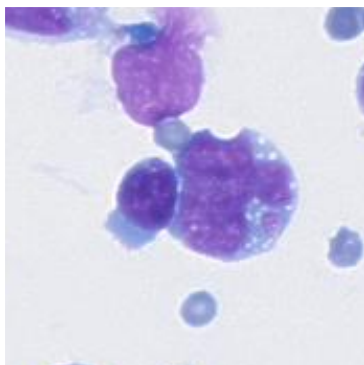


Capture 289575778  
Report Region

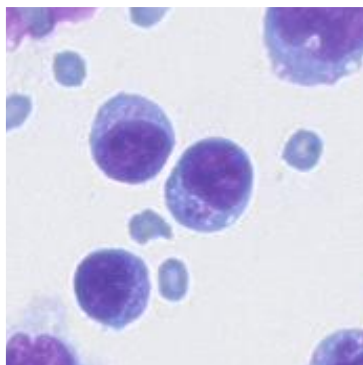


Capture 289576996  
Report Region

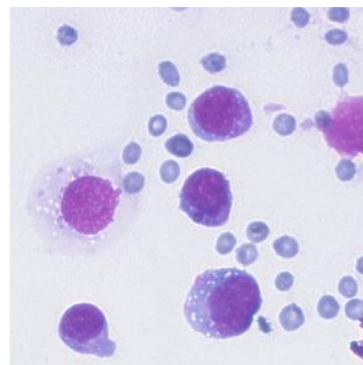




Capture 289576997  
Report Region



Capture 289576998  
Report Region



Capture 289576999  
Report Region

Specimen  
Abdominal effusion; 2 scans

#### Microscopic Description

Moderately sized scanned regions from two direct preparation fluid slides are examined. The samples are highly cellular and composed of a monomorphic population of large, atypical lymphocytes on a pale, basophilic, proteinaceous background with minimal blood and low numbers of non-degenerate neutrophils. The lymphocytes are large (approximately 1.5-2x the diameter of a neutrophil) with mildly increased amounts of basophilic cytoplasm. Many contain low numbers of chunky, eosinophilic granules. The nuclei are round to oval with finely stippled to smooth chromatin and 1-4 variably sized nucleoli.

#### Interpretation

Granular lymphoma

#### Comments

Granular lymphoma in the cat is a morphologically distinct subtype of lymphoma of T-cell or NK cell origin, which most commonly arises in the gastrointestinal tract and often involves regional lymph nodes. These cases have been reported to have poorer survival times as compared to other lymphoma subtypes though a recent retrospective has identified that a small subset of cases may harbor a more favorable prognosis (Finotello et al. Vet Comp Oncol. 2018; 16:159-166.) Circulating granular lymphocytes in the peripheral blood, neutrophilia, as well as increased serum liver enzymes, bilirubin, BUN, and creatinine are reported in many patients.

Carol Haak DVM, DACVECC, DACVP | USA, NY  
(GMT-5)  
4/x/2023 10:14 AM PDT

Contact Information: [ZVLdigitalcyto@zoetis.com](mailto:ZVLdigitalcyto@zoetis.com)

**Disclaimer:** This report and the results contained herein relate only to the section(s) of the slide(s) submitted for evaluation as received. Additional material or content present on other sections of the slide(s) or on other slide(s) not submitted for evaluation may compromise the accuracy of the diagnosis.

<b>Patient ID:</b>	<b>Clinic/Hospital:</b>
<b>Patient Name:</b>	
<b>Test ID:</b>	<b>Submitted Date:</b> 2/x/2022 11:28 AM PST
<b>Birth Date:</b>	<b>Finalized Date:</b> 2/x/2022 12:19 PM PST
<b>Age:</b> 6 months	
<b>Species:</b> Feline	
<b>Breed:</b> Siamese	
<b>Sex:</b> Male	

## Cytologic Evaluation

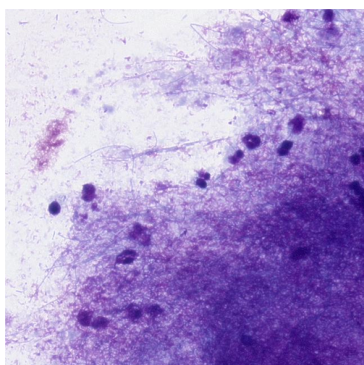
### Clinical History

Presented Feb/2022 for dyspnea. Thoracocentesis showed serosanguinous, sl opaque fluid (owner did not approve cytology); Convenia (Cefovecin) given. Dyspnea returned 1 day ago (patient was normal at home up to this point). Decreased appetite and activity since dyspnea recurred. Thoracocentesis today showed green, opaque fluid approx 150ml. Chemistry panel x/Feb/2022 WNL; CBC x/Feb/2022: lymphocytes 40.73 K/uL (0.92-6.88), monocytes 10.85 K/uL (0.05-0.67), neutrophils 2.86 K/uL (2.3-10.29). Pleural effusion (x/Feb/2022) TP 5 g/dL.

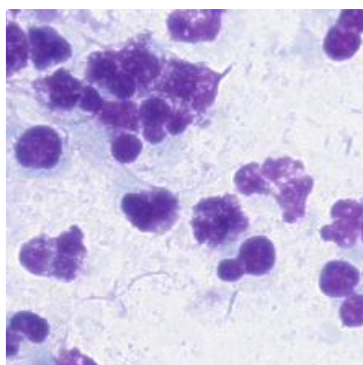
### Thorax Site 1 of 1

#### Cytology: Fluid Analysis

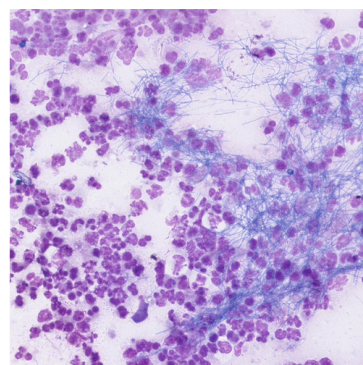
Fluid Detail	Result
Color	Green
Clarity	Opaque
Flocculent Material	Yes
Source	Pleural Effusion
PCV	-



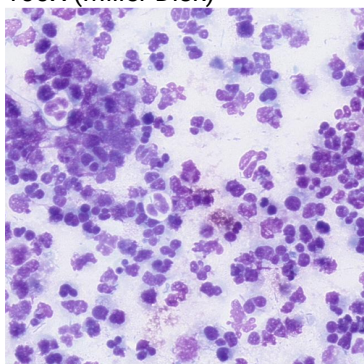
Capture 249454833  
100X (Miller Disk)



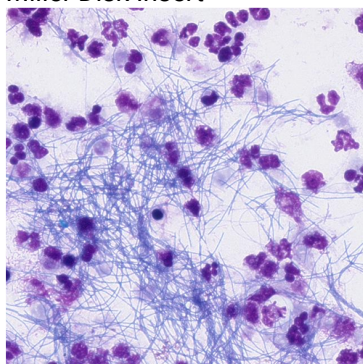
Capture 249454840  
Miller Disk Insert



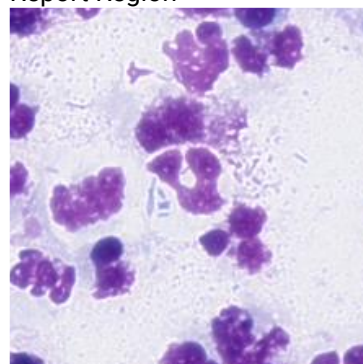
Capture 249454914  
Report Region



Capture 249454970  
100X (Miller Disk)



Capture 249455008  
100X (Miller Disk)



Capture 249455021  
Miller Disk Insert

Specimen  
Thoracic effusion

#### Microscopic Description

Scanned areas from 2 slides are reviewed. The preparation contains large numbers of inflammatory cells which are mostly variably degenerate and pyknotic or poorly preserved neutrophils (>90%) admixed with fewer poorly preserved mononuclear cells (possible macrophages and/or lymphocytes). The cell concentration is very high in this preparation and if unconcentrated cell estimate is above 500,000 cells/uL. Bacteria of variable morphology are present in large number. These include slender elongate filamentous forms often found in extracellular aggregates admixed with short to medium bacterial rods, which are also found occasionally within neutrophils on scanning. No neoplastic cells are identified.

#### Interpretation

Septic exudate with filamentous and rod shaped bacteria

#### Comments

Cytologic findings reflect septic pyothorax. Bacteria with filamentous morphology include *Actinomyces* or *Nocardia* spp among others. *Actinomyces* is frequently found in cases of pyothorax, often mixed with other bacteria, and aerobic and anaerobic culture are recommended in this case to fully characterize the bacterial population(s) observed. Additionally, notification of the laboratory as to cytologic differentials including *Actinomyces*/*Nocardia* is recommended as these agents may require prolonged culture for growth. Cause of pyothorax is not apparent from this preparation but broadly can be seen with direct inoculation of oral and environmental bacteria (e.g., bite wounds, migrating foreign body) as well as from local extension in cases of bacterial infection of the lungs, rupture of esophagus/trachea, or with hematogenous/lymphatic spread from distant sites.

Regarding the reported lymphocytosis in this patient on 2/x/2022, review of a blood film is recommended if not already performed to confirm or update this finding. An inflammatory leukogram would be most expected in this patient and when toxic change and left-shifting is prominent in the

neutrophil series this can sometimes can sometimes erroneously be classified as a lymphocytosis by automated hematology analyzers.

Thanks very much for taking the time to speak to me about this case. Your slide preparations were excellent and I am hoping all the best for Sushi and his family. Please do not hesitate to contact me if you have additional questions.

---

Mary Leissinger, DVM, MS, DACVP (Clinical) | Phone:  
2/x/2022 12:19 PM PST

**Contact Information:** [ZVLdigitalcyto@zoetis.com](mailto:ZVLdigitalcyto@zoetis.com)

**Disclaimer:** This report and the results contained herein relate only to the section(s) of the slide(s) submitted for evaluation as received. Additional material or content present on other sections of the slide(s) or on other slide(s) not submitted for evaluation may compromise the accuracy of the diagnosis.



<b>Patient ID:</b>		<b>Clinic/Hospital:</b>	
<b>Patient Name:</b>		<b>Submitted Date:</b>	<b>2/x/2023 8:09 PM PST</b>
<b>Test ID:</b>		<b>Finalized Date:</b>	<b>2/x/2023 8:56 PM PST</b>
<b>Birth Date:</b>			
<b>Age:</b>			
<b>Species:</b>	<b>2 years PYTHON</b>		
<b>Breed:</b>	<b>Stimson's python</b>		
<b>Sex:</b>	<b>Male</b>		

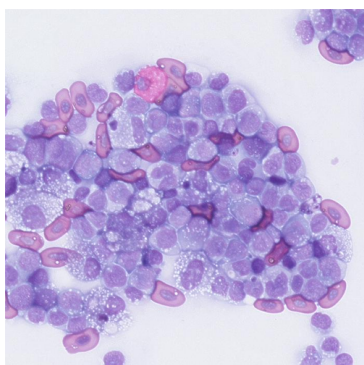
## Cytologic Evaluation

### Clinical History

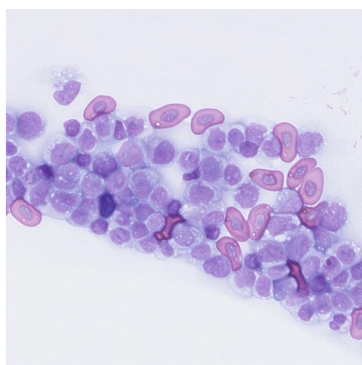
Tail tip injury

**Blood Smear** Site 1 of 1  
Cytology: Fluid Analysis

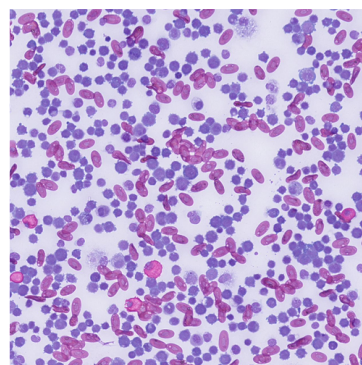
Fluid Detail	Result
Color	Red
Clarity	Opaque
Flocculent Material	No
Source	Peripheral Blood Smear
Total Protein	-
Hematocrit	-
Leukocyte Count	-
Platelet Count	-
Serum Appearance	-



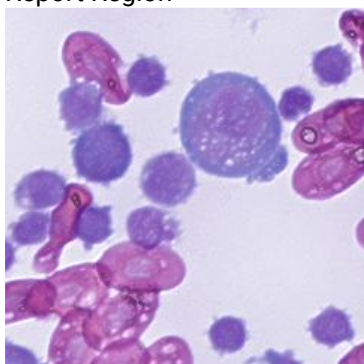
Capture 278159275  
Report Region



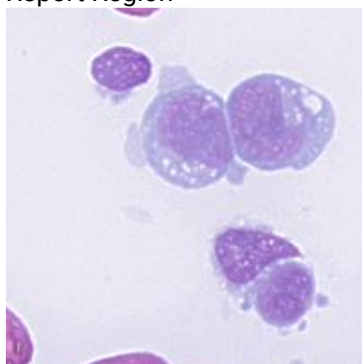
Capture 278159278  
Report Region



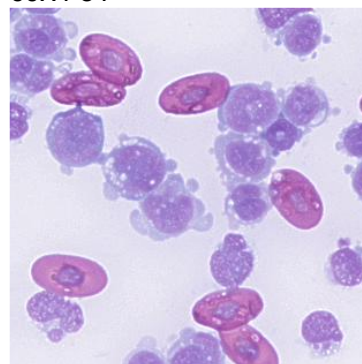
Capture 278159280  
50X FOV



Capture 278159286  
Report Region



Capture 278159292  
Report Region



Capture 278159293  
Report Region

Specimen  
Blood film

#### Microscopic Description

**RBC:** The erythroid density is decreased. Erythroid morphology is normal with no significant polychromasia.

**WBC:** The leukocyte density is severely increased with an estimate of at least  $500 \times 10^9/L$ . The differential is comprised of 94% mononuclear cells and 3% heterophils. The majority of the mononuclear cells are atypical, but resemble lymphoid cells. They range in size from 8-12  $\mu m$  and have moderately basophilic cytoplasm with small vacuoles. They often display membrane blebbing. Their nuclei are round to irregular with open, immature chromatin. Some display prominent nucleoli and mitotic figures are observed. Low numbers of small, mature lymphocytes are seen.

**Thrombocytes:** Thrombocytes appear decreased.

#### Interpretation

Acute leukemia (see comments)

#### Comments

The leukocyte estimate is markedly elevated and the vast majority of leukocytes are poorly-differentiated, immature cells consistent with acute leukemia. While I suspect lymphoid origin, I cannot rule out acute myeloid leukemia. Leukocytes appear to far outnumber red cells and I suspect a significant anemia is present. It does not appear regenerative. In addition, I also suspect thrombocytopenia.

I note a tail tip injury in the clinical history. While injury could incite an inflammatory leukogram, this is far beyond what is typically caused by inflammation alone and the atypical morphology of many of these cells is also not expected with inflammation.

Please do not hesitate to email me with further questions or additional history, follow-up.

---

Sarah Johnson, DVM, MS, DACVP | Phone: | US (Country Code: 1)  
2/x/2023 8:56 PM PST

**Contact Information:** [ZVLdigitalcyto@zoetis.com](mailto:ZVLdigitalcyto@zoetis.com)

**Disclaimer:** This report and the results contained herein relate only to the section(s) of the slide(s) submitted for evaluation as received. Additional material or content present on other sections of the slide(s) or on other slide(s) not submitted for evaluation may compromise the accuracy of the diagnosis.

<b>Patient ID:</b>	<b>Clinic/Hospital:</b>	
<b>Patient Name:</b>	<b>Submitted Date:</b>	<b>9/x/2022 12:29 PM PDT</b>
<b>Test ID:</b>	<b>Finalized Date:</b>	<b>9/x/2022 12:46 PM PDT</b>
<b>Birth Date:</b>		
<b>Age:</b>	<b>5 years</b>	
<b>Species:</b>	<b>Feline</b>	
<b>Breed:</b>	<b>Domestic Short Hair</b>	
<b>Sex:</b>	<b>Female Spayed</b>	

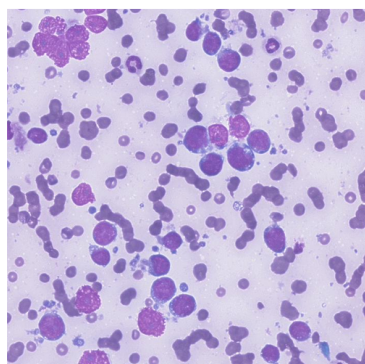
## Cytologic Evaluation

### Clinical History

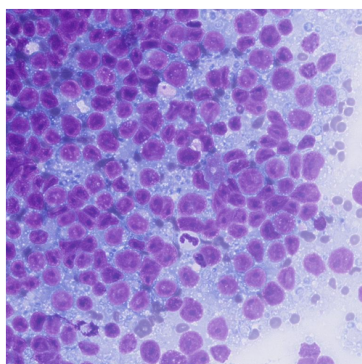
Weight loss, inappetence, stomach mass on ultrasound

**Stomach Mass** Site 1 of 1  
Cytology: Lesion Analysis

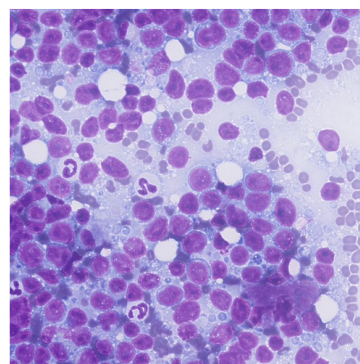
Lesion Detail	Result
Body Region	Intracavity
Lesion Type	FNA



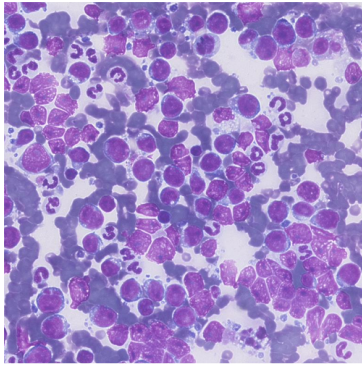
Capture 260711987  
Report Region



Capture 260712009  
Report Region



Capture 260712010  
Report Region



Capture 260712208  
Report Region

Specimen  
FNA, stomach mass

#### Microscopic Description

Two scans contain many variably preserved nucleated cells and erythrocytes; both are of very good diagnostic quality. The nucleated cells are comprised mostly (~90-95%) of large lymphocytes, with moderate numbers of nondegenerate neutrophils and rare small lymphocytes, macrophages, and eosinophils. The large lymphocytes have round to indented or cleaved, eccentric nuclei approximately 2.5-4x the diameter of an RBC, with finely stippled to pitted chromatin and 1-3 prominent, round nucleoli. Mitotic figures frequent. There is a small to moderately expanded amount of deep basophilic cytoplasm, sometimes with a paranuclear clear zone (Golgi) and several small discrete vacuoles. Many cytoplasmic fragments and ruptured, aggregated nuclei are in the background. No infectious organisms are identified.

#### Interpretation

Lymphoma (large cell); neutrophilic inflammation.

#### Comments

Cytologic findings indicate a large cell lymphoma. Additional diagnostics, including PCR for antigen receptor rearrangement (PARR), histopathology, or flow cytometry would be recommended for further subtyping. Flow cytometry and PARR test and sample information can be found at <https://vetmedbiosci.colostate.edu/chl/choose-a-test/>. Please contact me directly if you have any questions. My thoughts are with your patient and her family.

If complimentary consultation with a veterinary oncologist would be of interest in this case, please visit [ZoetisDX.com](https://zoetisdx.com) to request a consultation from a clinical specialist. If you are not currently a registered user on ZoetisDX, you can register your clinic on the main login page. If you would like help registering your clinic or have any questions about ZoetisDx and its full functionality, please reach out to your local customer support team. Please feel free to contact [ZVLdigitalcyto@zoetis.com](mailto:ZVLdigitalcyto@zoetis.com) with any pathology-related questions.

---

Annie Bauman, DVM, MS, DACVP (Clinical) | Mobile: xxx.xxx.xxxx  
(Country Code: 001)  
9/x/2022 12:46 PM PDT

Contact Information: [ZVLdigitalcyto@zoetis.com](mailto:ZVLdigitalcyto@zoetis.com)



<b>Patient ID:</b>		<b>Clinic/Hospital:</b>	
<b>Patient Name:</b>		<b>Submitted Date:</b>	<b>11/x/2022 3:55 PM UTC</b>
<b>Test ID:</b>		<b>Finalized Date:</b>	<b>11/x/2022 5:11 PM UTC</b>
<b>Birth Date:</b>			
<b>Age:</b>	<b>4 years</b>		
<b>Species:</b>	<b>Equine</b>		
<b>Breed:</b>	<b>Quarter Horse</b>		
<b>Gender:</b>	<b>Female</b>		

## Cytologic Evaluation

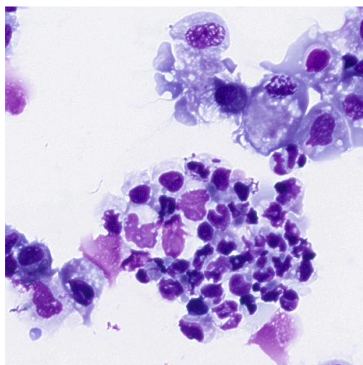
### Clinical History

No history provided for the horse.

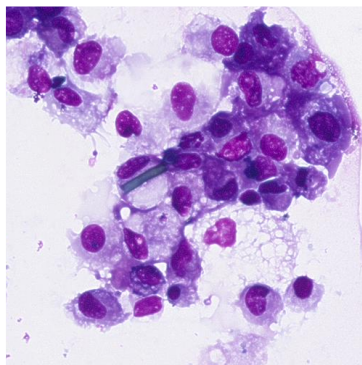
### Bronchoalveolar Lavage Fluid Site 1 of 1

Cytology: Fluid Analysis

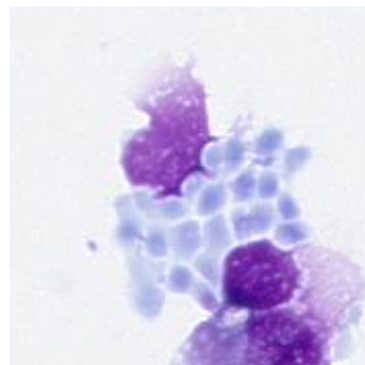
Fluid Detail	Result
Color	Colorless
Clarity	Clear
Flocculent Material	No
Source	Bronchoalveolar Lavage (BAL)



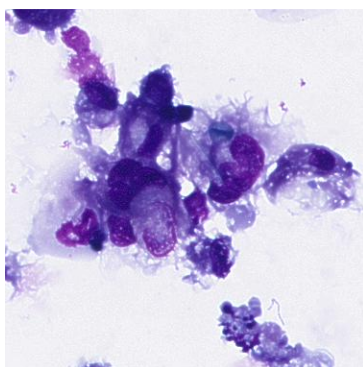
Capture 266749184  
Report Region



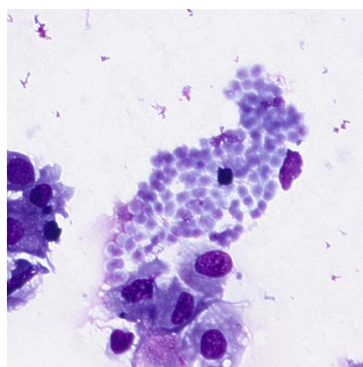
Capture 266749186  
Report Region



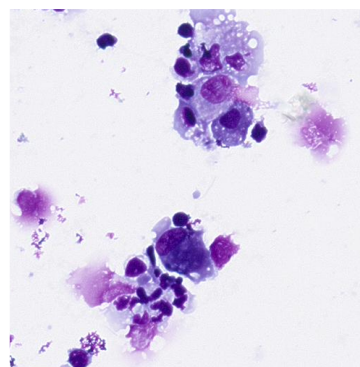
Capture 266749450  
Report Region



Capture 266749489  
Report Region



Capture 266749497  
Report Region



Capture 266749531  
Report Region

Specimen  
BAL - cytospin

#### Microscopic Description

Scanned areas from one slide are evaluated. The sample is of high nucleated cellularity and adequately to poorly preserved on a clear background. On 400 cell differential count, cells are composed of large mononuclear cells/macrophages (~67%), small lymphocytes (~20%) and neutrophils (~14%).- Neutrophils may be somewhat underestimated, as even when intact these cells appear poorly preserved, with swollen or pyknotic nuclear features which can be due to pre-analytic factors including sample storage/transport, though can also be seen with degenerative change. Macrophages occasionally contain green to yellow structures compatible with inhaled plant/fungal material (e.g., barn contaminants) that are likely non-pathogenic. Focally, the background contains extracellular aggregates of round to oval amphophilic staining structures (possible yeast/fungal contaminant). No overtly malignant cells are identified.

#### Interpretation

Increased proportion of neutrophils (~14%)  
Aggregates of extracellular structures, possible contaminant  
Some material phagocytized by macrophages, compatible with inhaled pollen/fungal elements

#### Comments

Correlate cytologic findings with clinical impression, total nucleated cell count, and physical and endoscopic findings for complete interpretation. Neutrophils appear overall mildly increased for a BAL sample, as can occur with infectious etiologies, particularly bacterial, as well as non-infectious conditions such as mild to moderate asthma (inflammatory airway disease), among other causes.- Material phagocytized within macrophages is compatible with non-pathogenic barn inhalants. Focally, the background also contains extracellular aggregates of pale staining round to oval structures, possibly overgrowth of a fungal contaminant related to storage or procedure. These structures are not morphologically compatible with common fungal pathogens of the respiratory tract, though are somewhat degraded in the sample. Take cytologic findings along with clinical impression and any pending diagnostics (e.g., culture) to guide additional diagnostic and therapeutic strategies.

Thank you for your submission and the provided clinical history. Please reach out directly if I can be of any further assistance with this case.

---

Mary Leissinger, DVM, MS, DACVP (Clinical) | Phone: xxx.xxx.xxxx| U.S. (Country Code: 1)  
11/x/2022 5:11 PM UTC

Contact Information: [ZVLdigitalcyto@zoetis.com](mailto:ZVLdigitalcyto@zoetis.com)

<b>Patient ID:</b>	<b>Clinic/Hospital:</b>
<b>Patient Name:</b>	<b>Submitted Date:</b> 1/x/2022 8:49 AM PST
<b>Test ID:</b>	<b>Finalized Date:</b> 1/x/2022 9:21 AM PST
<b>Birth Date:</b>	
<b>Age:</b> 10 years	
<b>Species:</b> Canine	
<b>Breed:</b> Labrador Retriever	
<b>Sex:</b> Female	

## Cytologic Evaluation

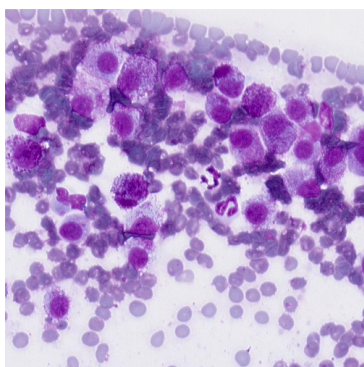
### Clinical History

08/2021 hard baseball size mass base of tail, fat, decomposed neutrophils, macrophages, & unidentified cells with multiple nucleoli; tried Pred & antibiotics rx, decreased in size to pt where we tried excision 10/2021 but was difficult w/scar tissue & muscle attachment; looked perfect after sx; 2 mo later acute (within a couple hrs) fluctuant swelling & bruising; again responded to Pred & abs, owner has continued Pred since but even then the swelling comes & goes within hrs; today 3" diameter, raised 1" bruised mass, now solid tissue, not painful, firmer lump within the large mass (2nd site slides) all at base of tail now growing right next to anal sphincter; The acute change in size is very strange to me; Owner is starting Benadryl today.

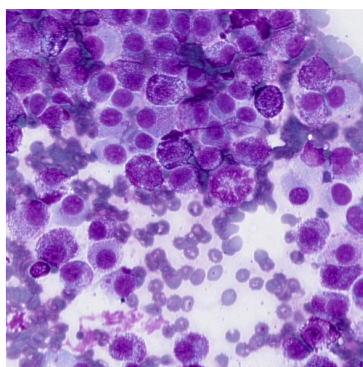
### Tail Base large mass Site 1 of 2

Cytology: Lesion Analysis

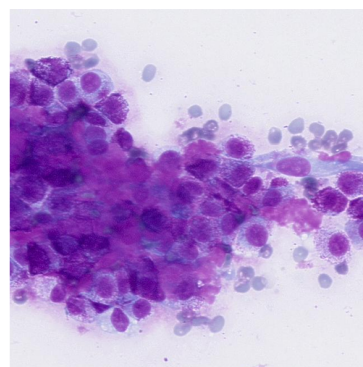
Lesion Detail	Result
Body Region (Other)	tail
Lesion Type	FNA



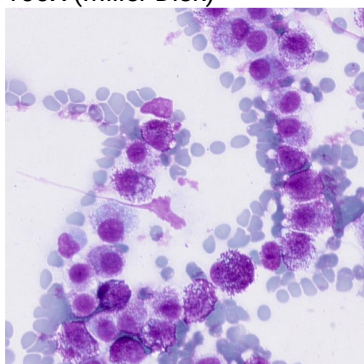
Capture 248743489  
100X (Miller Disk)



Capture 248743610  
100X (Miller Disk)



Capture 248743647  
100X (Miller Disk)



Capture 248743848  
100X (Miller Disk)

#### Specimen

FNA, large tail base mass, two scans.

#### Microscopic Description

Preparations are highly cellular with scant amounts of blood and cellular debris in clear to pale pink backgrounds. Mast cells predominate, both singly and in variably sized aggregates. Cells have round to oval centrally to paracentrally located nuclei ranging from 1.5-2.5 times the diameter of an erythrocyte with coarsely stippled chromatin and one to multiple small indistinct nucleoli, and small to moderate amounts of pale basophilic cytoplasm that contains scant to large numbers of variably-sized magenta to deep purple granules. Cells display mild to moderate anisocytosis and mild anisokaryosis. Occasional binucleate cells and mitotic figures are noted. Frequent spindloid to stellate mesenchymal cells (reactive fibroblasts) are seen. Small to moderate amounts of pink collagenous extracellular material is present.

#### Interpretation

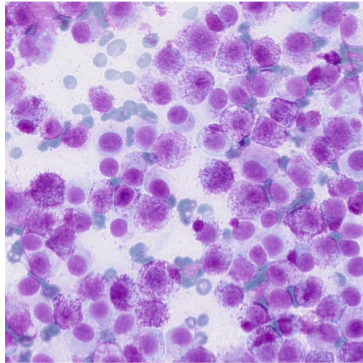
Mast cell neoplasm.

#### Comments

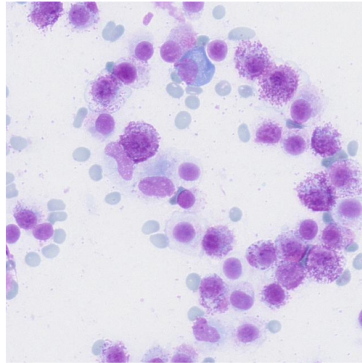
Histopathology for grading of this mass and staging of the patient, including evaluation of draining regional lymph nodes for metastases and abdominal imaging, are recommended. Do not hesitate to reach out to me directly if you have any questions.



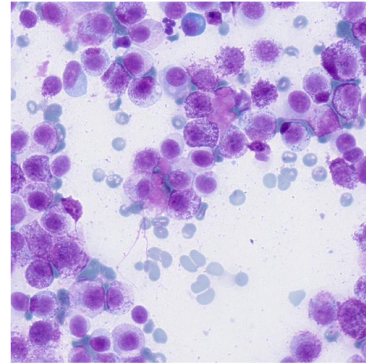
Lesion Detail	Result
Body Region (Other)	tail
Lesion Type	FNA



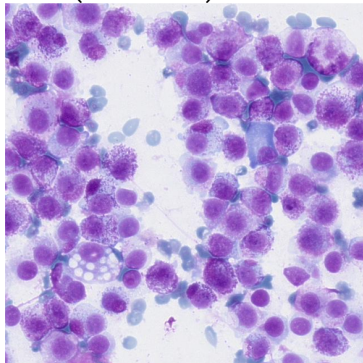
Capture 248743953  
100X (Miller Disk)



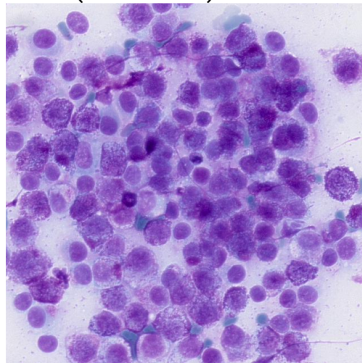
Capture 248743960  
100X (Miller Disk)



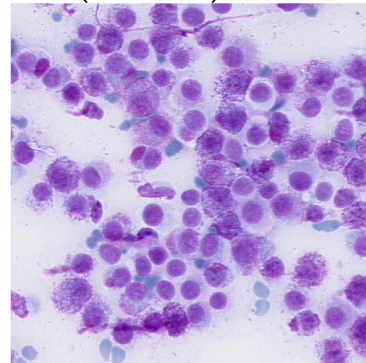
Capture 248743971  
100X (Miller Disk)



Capture 248744007  
100X (Miller Disk)



Capture 248744147  
100X (Miller Disk)



Capture 248744198  
100X (Miller Disk)

#### Specimen

FNA, firm mass within large tail base mass, two scans.

#### Microscopic Description

Preparations are highly cellular with scant amounts of blood and cellular debris in clear to pale pink backgrounds. Mast cells predominate, both singly and in variably sized aggregates. Cells have round to oval centrally to paracentrally located nuclei ranging from 1.5-2.5 times the diameter of an erythrocyte with coarsely stippled chromatin and one to multiple small indistinct nucleoli, and small to moderate amounts of pale basophilic cytoplasm that contains scant to large numbers of variably-sized magenta to deep purple granules. Cells display mild to moderate anisocytosis and mild anisokaryosis. Occasional binucleate cells and mitotic figures are noted. Frequent spindloid to stellate mesenchymal cells (reactive fibroblasts) are seen. Small to moderate amounts of pink collagenous extracellular material is present.

#### Interpretation

Mast cell neoplasm.

#### Comments

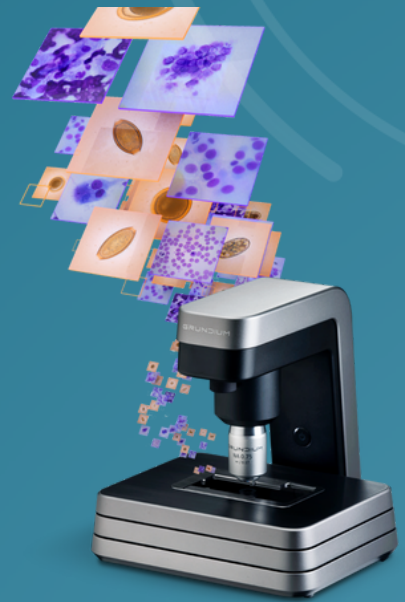
Histopathology for grading of this mass and staging of the patient, including evaluation of draining regional lymph nodes for metastases and abdominal imaging, are recommended. Do not hesitate to reach out to me directly if you have any questions.



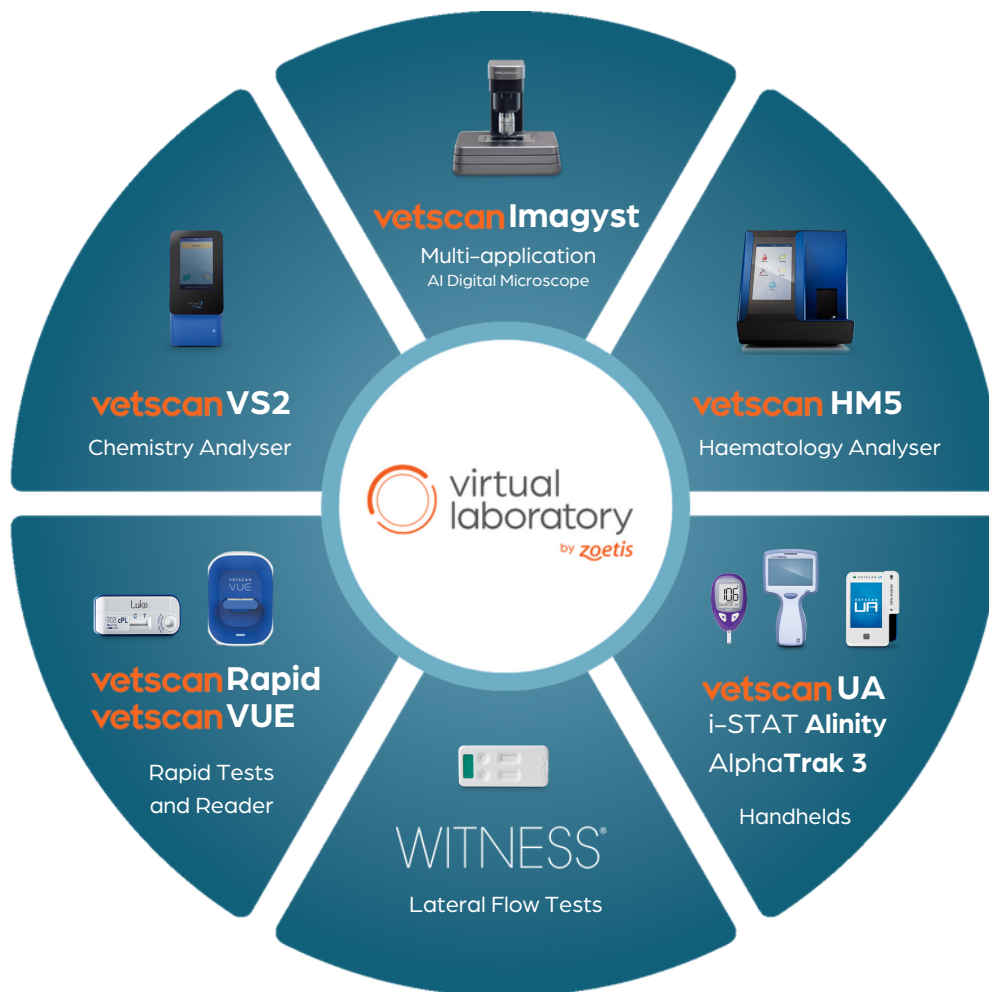ZOETIS DIAGNOSTICS

LOOK DEEPER

# Clinical Consultation Reports



virtual  
laboratory  
by zoetis



LOOK DEEPER

zoetis



**Veterinarian:**

**xx August 2022**

**Hospital Name:**

**Patient Name:** Fiona 12 yr FS  
CKCS

---

### **Zoetis Clinical Consultation Service Report**

**Clinical History** Suspect IMTP in dog with CHF, Labwork Performed 4 June 2022 (Hw, Ehr, Ana, Lyme Neg), TP-8, WBC ~12,000, HCT ~ 29%, Platelets 0 and 3. \*all labwork run in house, No slide review seen.

### **Summary of Consultation**

#### **Problem List:**

1. 4/6 left systolic heart murmur: Echocardiogram- Cardiologist rec. start enal. Spiro, vetmedin
2. Severe Dental disease
3. Severe thrombocytopenia on former June 2022 and Aug 2022 labs
4. Anemia non regenerative 29-30%
5. Elevated Total Solids: (globs and albumin, or 1 or the other?)

### **Case Interpretation**

Fiona's breed makes interpreting her platelets challenging as Cavaliers up to 50% have macrothrombocytopenia. Usually, when platelets are less than 10,000 then there are some clinical signs such as melena, petechia, bleeding gums etc. Sometimes this can be delayed. She is a new patient to you, so we don't have a "point of reference, but perhaps could get any former labwork in her life to compare platelet numbers?"

Typically, platelets are either not being made in the bone marrow (after TPO stimulation from the liver), or they are being broken down, or they are being lost (hemorrhage) or even sequestered in the spleen. If her total protein was lower, hemorrhage would be higher on the list, but with a high Total protein, it is less likely. Additionally without a history of toxicity or infectious disease, it would be strange to have a bone marrow problem though it is still on the list with the anemia present. That leaves either breed related values that are lower than normal, destruction or lastly sequestration.

I would first ask the pathologist that read her recent smear for an estimated platelet number. I would then recommend performing some diagnostics to make sure there is not an underlying cause that may be leading to a secondary immune mediated destructions (abdominal ultrasound, repeated chemistry, fungal/additional tick testing if there is geographic/travel exposure, and a urinalysis).

### **Considerations for further testing**

1. Estimated platelet number from recent slide review

2. Urinalysis to check for proteinuria and any bilirubin/hematuria
3. Abdominal imaging to evaluate if there is ascites, liver/spleen changes, lymph nodes size/adrenals, etc.
4. Repeat chest rads to evaluate any current CHF and any enlarged Lymph nodes
5. Repeat chemistry to look for changes and also repeat the CBC for another review (platelet lifespan is 7-10 days and canine RBC 120 days- look for clues for agglutination, toxic changes to neutrophils, bands, or even aggregates noted on slide
6. Have owner thoroughly check ears, eyes, belly and under tail of skin for petechia
7. **Rectal to look for melena/hematochezia**

### ***Treatment Considerations***

1. If there is supporting evidence of true immune destruction versus breed related platelet abnormalities, then cyclosporine (Atopica) or Neoral (microemulsified cyclosporine) at 5mg/kg BID is safer to start versus steroids for a patient with heart disease/recovering CHF. It takes up to 1 week for cyclosporine to become effective so a slow taper starting at 3-4 weeks lasting 3-6 months is usually indicated in cases of ITP.

\*Right now, Fiona seems stable and non-clinical for her platelets, so we have some time to do some investigating. I would not reach for vincristine or Human IVIG at this time, as it is unclear if this is truly Idiopathic ITP, her age at 12 yrs makes me pause as well that there could be an underlying issue (neoplastic/infectious, etc) that could also be driving the low platelets as well as her breed.

\*Please reach out if we can be of any further help.

### ***Further Resources***

---

Thank you for your case submission to our Zoetis Clinical Consultation Service. If you would like to discuss this case further, please don't hesitate to book another consultation or request further email advice via [ZoetisDx](#).

Regards,

Jennifer E. Slovak DVM, MS, DACVIM

<p><b>Disclaimer:</b> This report and any results, diagnosis, advice or other information contained herein regarding considerations for further testing, treatment, prognosis, or otherwise are based entirely on the case information provided by the veterinarian as of the date of this report. Additional case information not submitted for evaluation may alter or compromise the accuracy of this report.</p>
--



**Veterinarian:**

**3 March 2021**

**Hospital Name:** Veterinary Hospital

**Patient Name:** Wanda

---

## **Zoetis Clinical Consultation Service Report**

### **Clinical History**

Clinical Question(s) : Wanda's owner reports that she has been having trouble jumping on the couch and seems more lethargic over the past 7 days. Her appetite is variable, and the owner admits they do not closely monitor Wanda's food intake. No vomiting or diarrhea has been noted. Wanda was diagnosed with chronic renal failure (CRF) about 12 months ago (IRIS stage 2) and is currently on a prescription renal diet

Additional Comments : BUN and creatinine have been monitored about every 6 months at their local clinic and have remained mildly elevated according to the owner.

### **Summary of Consultation**

Wanda: 12 yr FS DSH Labwork available for review March 2021: CBC/Chemistries/UA/T4.

### **Problem List**

1. CKD Stage 2 (unknown BP), Crea: 348 umol/L, BUN: 15.0 umol/L, Alb: 21 g/L,
2. K: 2.20 mmol/L. SDMA: 27.
3. BCS 5/9
4. MCS 2/3- Very Mild Cachexia
5. Anemia - HCT 21.1% - Likely anemia of chronic disease
6. USG 1.022, UPC: 0.31 (Borderline), Inactive Sediment.

### **Case Interpretation**

Wanda is an interesting case. She had been categorized, and monitored as an IRIS Stage 2 CKD for the past 12 months. However, she is apparently still able to concentrate. Occasionally we will see an atypical CKD that can still concentrate, but still have CKD. But the SDMA confirms Wanda is within the spectrum of CKD. There are several clinical reasons to explain her recent onset of lethargy and reticence to jump on the couch. Osteoarthritis is a consideration, but since hypokalemia can cause muscle weakness, her history of CKD and the current moderate to marked hypokalemia observed in certain case of CKD may be the cause.

Hypokalemia is found in 20-30% of cats with CKD. As the kidneys progressively continue to fail, the ability to conserve potassium is reduced. This leads to overdepletion of potassium. These patients may also have a decreased appetite that could lead to a decreased intake of potassium.

### **Considerations for further testing**

1. Blood pressure monitoring.
2. Serum Potassium monitoring.
3. Continue CKD parameter Monitoring (CBC for Hct, Chemistry, UA, SDMA, every 2-3 months.

### **Treatment considerations**

1. Hospitalization, IV fluids to correct dehydration.
2. Monitor potassium as the patient's hydration is corrected. Consider adding potassium supplementation (KCl) to the IV fluid administered.
3. Consider oral Potassium supplementation if hypokalemia is recurrent.
4. Consider appetite stimulation if necessary- Mirtazapine
5. Monitor phosphorus levels & using phosphate binders if diet cannot control the values
6. Consider Darbopoeitin if anemia worsens (HCT in the low 20s)

### **Further resources**

1. [http://www.iris-kidney.com/pdf/2\\_IRIS\\_Staging\\_of\\_CKD\\_2021.pdf](http://www.iris-kidney.com/pdf/2_IRIS_Staging_of_CKD_2021.pdf)
  2. Elliott J, Barber PJ. Feline chronic renal failure: clinical findings in 80 cases diagnosed between 1992 and 1995. J Small Anim Pract. 1998;39(2):78-85. doi: 10.1111/j.1748-5827.1998.tb03598.x
-



Thank you for your case submission to our Zoetis Clinical Consultation Service. If you would like to discuss this case further, please don't hesitate to book another consultation or request further email advice via [ZoetisDx](#).

Regards,  
Jennifer Slovak, DVM, MS, DACVIM (SAIM)

**Disclaimer:** This report and any results, diagnosis, advice or other information contained herein regarding considerations for further testing, treatment, prognosis, or otherwise are based entirely on the case information provided by the veterinarian as of the date of this report. Additional case information not submitted for evaluation may alter or compromise the accuracy of this report.



**Veterinarian:**

**6 June 2023**

**Hospital Name:**

**Patient Name:**

Sammy

---

### **Zoetis Clinical Consultation Service Report**

#### **Clinical History**

Biting and licking abdomen for the past 2 months. Increased aggression when touched. Red, ulcerated lesions on dorsum and mildly enlarged popliteal lymph nodes. Fine needle aspirates of popliteal lymph nodes consistent with reactive lymph nodes. AI derm cytology of skin lesions shows mixed population of neutrophils (containing bacteria), eosinophils and macrophages.

#### **Summary of Consultation**

Dear Dr. Davies,

Thank you for using Zoetis Clinical Consultation Service! The clinical history and AI derm results are consistent with feline eosinophilic granuloma complex. The AI derm results also show evidence of secondary bacterial infection (neutrophils with intracellular cocci).

Eosinophilic granuloma complex is not a primary diagnosis in itself, but rather a response to an underlying allergic disease/hypersensitivity. Further diagnostic investigation is required to identify underlying causes such as flea allergy dermatitis, mosquito bite hypersensitivity, feline atopic skin syndrome and adverse food reaction. Eosinophilic granuloma complex lesions are commonly eroded or ulcerated, and therefore secondary bacterial infections are very common.

#### **Considerations for Further Testing and Treatment**

Treatment of the secondary bacterial infection: given that the bacteria were identified as cocci, an antibiotic with activity against gram positive organisms is recommended, such as cefalexin. For a cat of this weight, I would typically recommend a total dose of 70mg cefalexin PO BID for 21 days.

-Treat for ectoparasites: I recommend administering an isoxazoline ectoparasiticide to make sure that ectoparasites are not contributing to the pathogenesis.

-Diet trial: I would advise a strict hydrolyzed diet trial for 8 weeks. It is extremely important that a commercial hydrolyzed protein diet is fed as Sammy's exclusive diet during this time- any other dietary protein sources given during this time (e.g. treats, or access to any other type of cat food) will greatly impair the efficacy of this trial.

Once the diet has been fed for 8 weeks, the clinical response can be assessed. If Sammy's lesions have resolved, this positive response to the diet trial is consistent with a food allergy and the hydrolyzed diet should be continued long-term. If Sammy's lesions still persist, and he is still up to date on ectoparasiticide therapy, then we are very likely dealing with feline atopic skin syndrome.

For management of feline atopic skin syndrome, prednisolone is often used as a first line treatment. Usually I will start with 2 mg/kg/day of prednisolone for 5-7 days, then halve that dose daily for another 5-7 days, and then reduce to every other day dosing. I will continue to gradually taper the prednisolone dose each week with the aim to maintain Sammy on the lowest possible dose that will prevent the recurrence of lesions. Alternatively, cyclosporine can be used in cats as a first-line treatment for atopic dermatitis, or in cats that do not have a satisfactory response to prednisolone therapy. A starting dose of 7mg/kg/day is suggested. This dose should be continued until lesions resolve, and thereafter can be gradually tapered over a period of several weeks to the lowest possible dose that will prevent lesion recurrence.

Another consideration could be allergy immunotherapy, but I would typically try prednisolone or cyclosporine first. I hope this information helps- please feel free to request further advice if I can be of further assistance.

## Further Resources

---

Thank you for your case submission to our Zoetis Clinical Consultation Service. If you would like to discuss this case further, please don't hesitate to book another consultation or request further email advice via [ZoetisDx](#).

Regards,

Dr John Smith DVM, Diplomate ACVD

<p><b>Disclaimer:</b> This report and any results, diagnosis, advice or other information contained herein regarding considerations for further testing, treatment, prognosis, or otherwise are based entirely on the case information provided by the veterinarian as of the date of this report. Additional case information not submitted for evaluation may alter or compromise the accuracy of this report.</p>
--

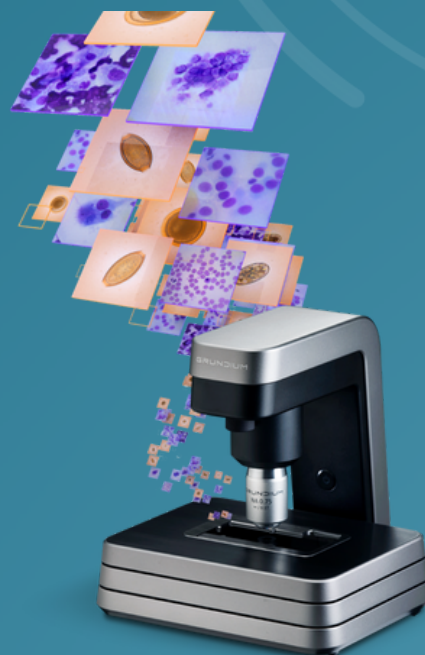
ZOETIS DIAGNOSTICS

# LOOK DEEPER

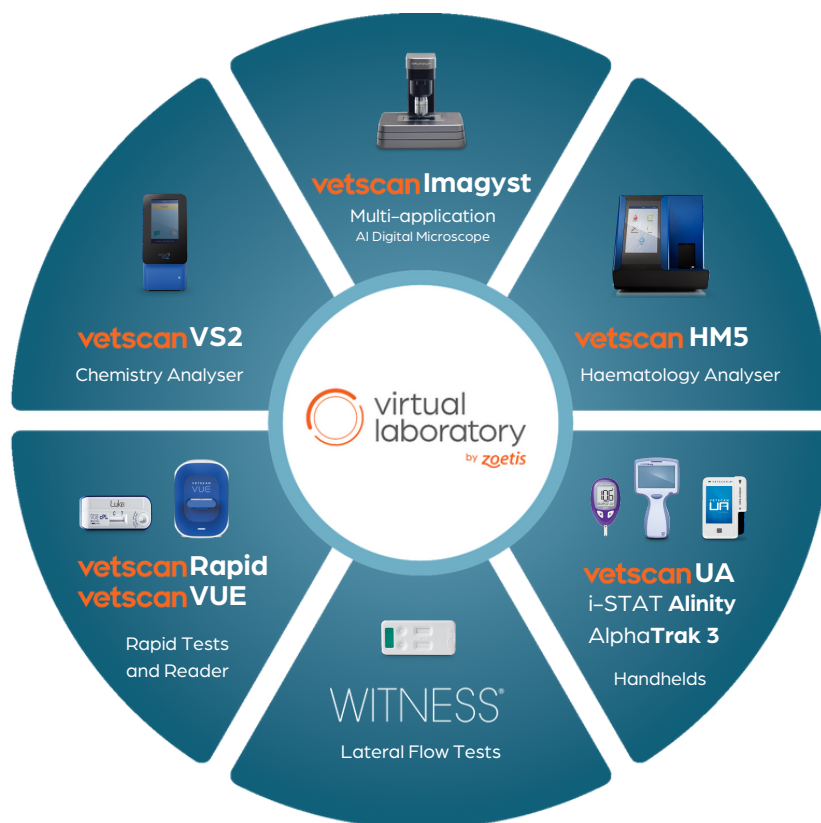## Zoetis Virtual Laboratory

Bringing specialist-level  
medicine directly into your clinic

Introducing Zoetis Virtual Laboratory — a unique online platform of interconnected diagnostic solutions. Vetscan Imagyst is central to the Virtual Laboratory offering, as it seamlessly unites innovative AI-based diagnostic testing at the point of care with real human clinical pathology expertise, for insights that inform treatment decisions and elevate patient care.



 virtual  
laboratory  
by zoetis



LOOK DEEPER

Further information can be obtained from Zoetis UK Ltd. Birchwood Building,  
Springfield Drive, Leatherhead, Surrey, KT22 7LP • [www.zoetis.co.uk](http://www.zoetis.co.uk)  
Customer support 0345 300 8034 • [CustomerSupportUK@zoetis.com](mailto:CustomerSupportUK@zoetis.com)  
Produced June 2024 MM-34451

**zoetis**